

Localized Papular Mucinosis With IgA Nephropathy

A Case Report

Peng Wang, MD; Hanjun Yang, MD; Yuping Ran, MD, PhD

Background: Papular mucinosis is an idiopathic cutaneous mucinosis. It includes 3 clinicopathologic subsets according to the recent Rongioletti classification: a generalized papular form, a localized form, and atypical forms. The localized form is subdivided into 5 subtypes. The atypical form does not meet the criteria for either the generalized papular form or the localized forms and includes localized forms with monoclonal gammopathy and/or systemic symptoms.

Observations: We describe a 37-year-old man who had multiple small, waxy papular lesions on the neck for 4 years. One year after the lesions first appeared, he developed IgA nephropathy. No paraproteinemia or thyroid dysfunction

was observed. Histologic examination of the skin lesions showed mucin deposits in the upper dermis. Alcian blue–positive mucin was also found in the renal interstitium and around some vessels and capillary loops. A diagnosis of localized papular mucinosis with IgA nephropathy (atypical form) was made after the biopsy.

Conclusions: The patient showed an unusual manifestation of localized papular mucinosis with the lesions confined to the neck and IgA nephropathy. Alcian blue staining is a useful way to determine kidney involvement of papular mucinosis.

Arch Dermatol. 2011;147(5):599-602

PAPULAR MUCINOSIS (PM) (aka, lichen myxedematosus) is a disorder characterized by lichenoid papules, nodules, and/or plaques due to mucin dermal deposition. In 1953, Montgomery and Underwood¹ established a clinical classification of PM with 4 subtypes: (1) generalized lichenoid papular eruptions; (2) discrete papular form; (3) localized or generalized lichenoid plaque form; and (4) urticarial plaques and nodular eruptions. The updated Rongioletti classification² includes 3 clinicopathologic subsets: (1) generalized PM (scleromyxedema) with systemic manifestations; (2) localized PM without sclerotic features, paraproteinemia, or systemic involvement; and (3) atypical forms, not meeting the criteria for either scleromyxedema or the localized form, including localized forms with paraproteinemia and/or systemic symptoms. The localized form is subdivided into 5 sub-subtypes: (1) discrete PM; (2) acral persistent PM (APPM); (3) self-healing PM (SHPM); (4) PM of infancy; and (5) nodular PM. In this study, we describe a man with PM confined to the neck who later developed IgA nephropathy. The case represents a novel

form of localized PM, a “confined” form with renal involvement.

REPORT OF A CASE

A 37-year-old Chinese man presented with multiple small, asymptomatic, waxy papular lesions that had been on his neck for 4 years. Over the years, he had continued to develop new lesions, while the preexisting lesions coalesced into plaques. However, the lesions remained confined to the neck and did not spread to other parts of the body. His family history was negative. A review of systems revealed that 1 year after the lesions' first appearance, he had developed symptoms of flank pain, increased nocturia, hematuria, and albuminuria. There was no hypertension, edema, or other symptoms of chronic kidney disease. Through renal biopsy, he had been diagnosed as having IgA nephropathy (grade II). There was no other systemic involvement. Prednisone was given but was unsatisfactory in controlling both the skin and the renal symptoms. His renal function remained normal during these years.

Skin examination revealed multiple firm, waxy, opalescent, flat-topped, 2- to

Author Affiliations:

Department of Dermatovenereology, West China Hospital, Sichuan University, Chengdu, People's Republic of China.

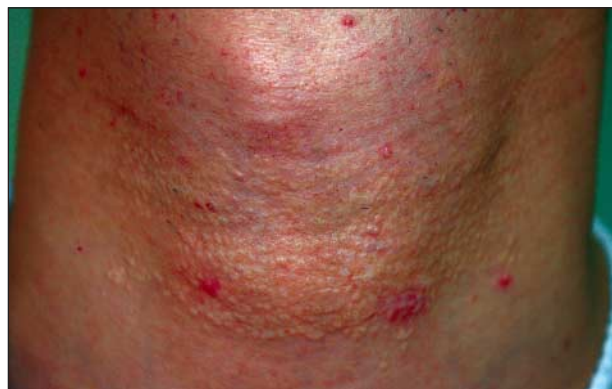

Figure 1. The patient presented with multiple firm, opalescent, flat-topped papules on the neck ranging in size from 2 to 4 mm. The coalescence of papules formed a 10 × 6-cm linear plaque.

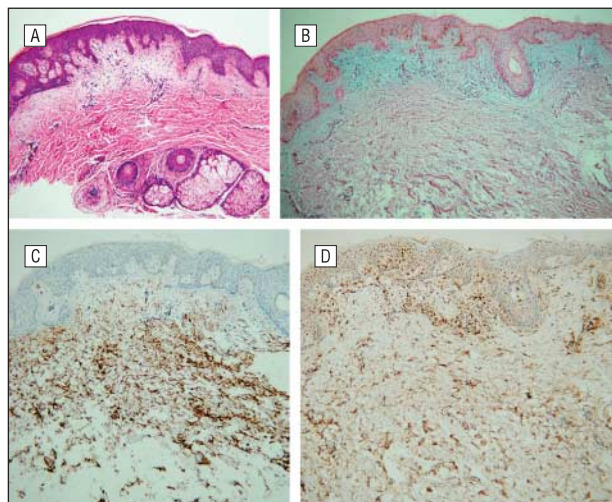


Figure 2. Histopathologic and immunohistochemical specimens. A, Loosely separated collagen fibers in the upper dermis (hematoxylin-eosin, original magnification ×100). B, Mucinous stroma stained positively with Alcian blue (original magnification ×100). C, Expression of CD34 cells within the mucinous stroma and in the deeper part of the dermis (original magnification ×100). D, Expression of factor XIIIa cells in the periphery of the mucinous stroma (original magnification ×100).

4-mm papules. The coalesced papules formed a 12 × 6-cm linear plaque on the neck. There were a few discrete and irregularly distributed papules around the plaque (**Figure 1**).

METHODS

Routine urinalysis revealed macroalbuminuria and hematuria; the 24-hour urinary protein level was 2.14 g. Routine blood test results, thyroid function, and liver and renal function were all normal. Levels of serum IgG, IgA, IgM, IgE, C4, circulating immune complexes, anti-double-stranded DNA, anti-ribonuclear protein, antinuclear antibody, anti-Sm, anti-Ro (SSA), anti-La (SSB), and Scl-70 antibodies were within normal limits. The patient tested negative for human immunodeficiency virus.

Color Doppler ultrasonographic examination of the thyroid gland showed no abnormalities.

Histologic examination of the skin lesions showed loosely separated collagen fibers in the upper dermis, suggesting mucinous deposition, and some dermal mesenchymal cells within

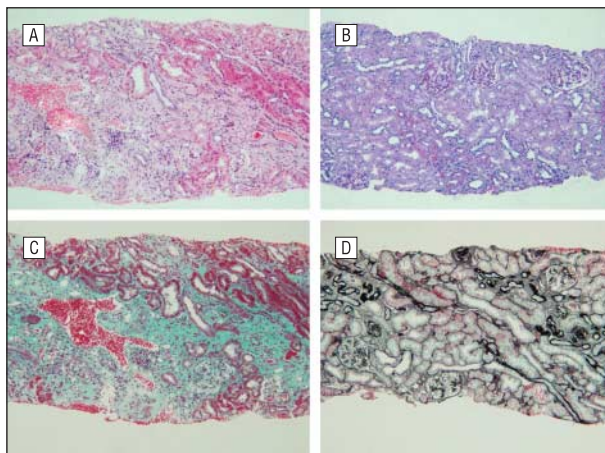


Figure 3. Histologic examination of the renal tissue (original magnification ×100 for all panels). Visible are focal mesangial proliferation, sclerosis, and adhesion of the glomeruli; atrophic renal tubules; and proliferation of the renal interstitium. A, Hematoxylin-eosin; B, periodic acid-Schiff stain; C, Masson trichrome stain; and D, periodic acid-silver methenamine stain.

and surrounding the mucinous stroma (**Figure 2A**). The mucinous stroma stained positively with Alcian blue (pH, 2.5) (**Figure 2B**) but not with toluidine blue (pH, 7.0). Immunohistochemically, the mesenchymal cells tested strongly vimentin positive (Dako, Carpinteria, California), and some of them were also positive for either CD34 (Dako) or factor XIIIa (Biogenesis Ltd, Poole, England) (**Figure 2C** and **D**). The CD34⁺ cells were found mainly within the mucinous stroma and in the deeper part of the dermis (**Figure 2C**). Factor XIIIa-positive cells were predominant in the periphery of the mucinous stroma (**Figure 2D**). The mesenchymal cells tested negative for desmin (Dako) and S-100. (Maixin-Bio, Fuzhou, China).

Histologic examination of the renal tissue showed focal mesangial proliferation, sclerosis, and adhesion of the glomeruli; a moderate fibrous crescent formation could also be seen in the glomeruli. The glomerular capsules showed thickening and layering in the corticomedullary junction, and 10% of the renal tubules were atrophic. There was proliferation of the renal interstitium around the atrophic tubules and in the corticomedullary junction (**Figure 3**). Immunofluorescence analysis showed deposits of IgA, mainly in the mesangium (++) , and segmental or focal deposits of IgG in glomeruli (++) ; IgM, C3, C4, C1q, and fibronectin findings were negative.

After processing renal tissue with Alcian blue, we also found positively stained mucin deposits in the renal interstitium around some arterioles, venules, renal tubules, and capillary loops, part of them even projecting into the glomerular capsule, and we found some mucin deposits in the mesangium (**Figure 4A** and **B**). These mucinous depositions were shown again through staining with Alcian blue/periodic acid-Schiff (**Figure 4C** and **D**). To show the correspondence, we also stained with hematoxylin-eosin (HE). The Alcian blue-positive mucinous depositions corresponded to the HE stain of loosely separated collagen fibers and pale-staining areas. Increased numbers of vimentin-positive spindle-shaped cells were found in the mucinous deposition areas. These cells were negative for CD34 and factor XIIIa.

We proposed vaporizing the lesions with a carbon dioxide laser, but the patient declined the treatment because he had no cosmetic concerns.

COMMENT

Though Rongioletti and Rebora² made significant contributions to the clinical classification of PM, there re-

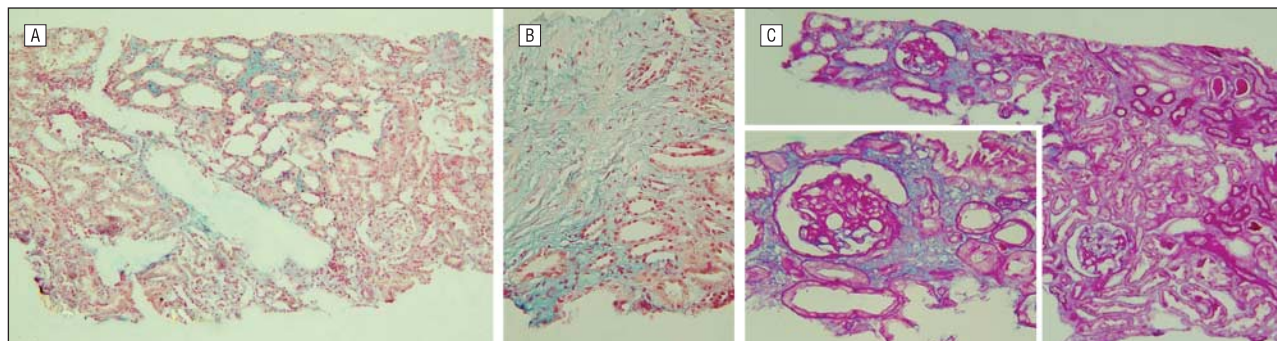


Figure 4. Histopathologic specimens. Alcian blue (AB)-positive mucin deposits were found in the renal interstitium around some arterioles, venules, and tubules (A, original magnification $\times 100$) and also at the corticomedullary junction (B, original magnification $\times 400$). C, Mucin deposits were found in the capillary loops and projected into the glomerular capsule and in the mesangium with mesangial proliferation (AB-periodic acid-Schiff (PAS) stain, original magnification $\times 100$) (inset, AB-PAS, original magnification $\times 400$).

main many cases that are not well characterized. Borradori et al³ report a case of APPM with IgA monoclonal gammopathy that challenges the view that absence of paraproteinemia is a peculiar characteristic of APPM. Chen et al⁴ report congenital cutaneous mucinosis with spontaneous regression. And our case also presents such an example. Because the lesions were confined to the neck, we believe it should belong to the localized form, but it cannot be categorized into any of the 5 localized subtypes, especially considering the renal association. Discrete PM is inappropriate because it is characterized by isolated papules, which present in a symmetric disposition, mainly on the trunk and extremities.⁵⁻⁷ The manifestation of this form is clearly different from our case. It is also necessary to differentiate our patient's condition from mucinous nevus and SHPM. Mucinous nevus presents as asymmetric and localized papules at birth or shortly after birth,⁸ and SHPM spontaneously resolves within a few weeks or not more than 2 years after onset.⁹

The histopathologic findings of PM are similar. Alcian blue-positive mucin is often deposited in the upper and mid dermis, and the number of dermal mesenchymal cells is increased.² Immunohistochemical analyses in some cases of PM have detected CD34⁺ or factor XIIIa-positive dermal dendritic cells (DDCs) within and surrounding the mucin deposition,¹⁰⁻¹² suggesting that they might have participated in the dermal deposition of mucin. Because vimentin is a general mesenchymal marker and DDCs have been characterized immunohistochemically by the presence of factor XIIIa¹³ or CD34,¹⁴ we also tested for these immunohistochemical markers. The findings in our case showed that vimentin-positive dermal mesenchymal cells were strongly expressed within and surrounding the mucinous stroma. The CD34⁺ DDCs were found mainly within the mucinous stroma and in the deeper part of the dermis. Factor XIIIa-positive DDCs were located predominantly in the periphery of the mucinous stroma. These cells tested negative for desmin and S-100. Thus, we concluded that CD34⁺ DDCs within the mucinous stroma, in combination with factor XIIIa-positive DDCs in the perilesional area, may have participated in the dermal deposition of mucin.

In the classification system of Montgomery and Underwood,¹ the discrete papular form and localized form

are 2 different subtypes. The localized form, in the Rongioletti classification, does not run a disabling course. In fact, as *localized* literally means confined or restricted to a particular location, the Rongioletti system likely caused misunderstandings by assigning too many additional definitions to the localized form. We propose adding the *localized lichenoid plaque form* as a new subtype of the localized papular form described by Rongioletti and Rebora,² defined as lichenoid plaque eruptions confined or restricted to a particular location, which would describe the lesions in our case. When it has an internal association, as in our case, we classify it as an atypical form.

Although scleromyxedema is associated most frequently with monoclonal gammopathy and various systemic disorders,¹⁵ there have been cases of localized PM showing systemic involvement.^{12,16} They are classified as atypical forms. However, kidney involvement is seldom reported in either the generalized (scleromyxedema) or localized forms (atypical type).¹⁷ In 2007, Peeters et al¹⁸ reported a patient with scleromyxedema and chronic kidney disease. Biopsy specimen analysis revealed that renal failure was due to accumulation of Alcian blue-positive mucin depositions in the wall of the arterioles, which caused concentric narrowing of the renal arterioles and severe glomerular ischemia.

We think that our patient's history of localized PM was involved with his development of his IgA nephropathy. We tested renal tissue with Alcian blue and found Alcian blue-positive mucin deposition in the renal interstitium and capillary loops. Part of the mucin even projected into the glomerular capsules and was deposited in the mesangium. We also found that the number of vimentin-positive spindle-shaped cells was increased in the mucinous deposition areas. These cells tested negative for CD34 and factor XIIIa, which suggests that they were fibroblasts. The proliferation of fibroblasts can cause mucin deposition in the skin,¹⁷ which may also cause mucin deposition in the kidney. As Peeters et al¹⁸ reported, mucin deposition around vessels can cause narrowing of renal vessels and glomerular ischemia. It is possible that in our case, the proliferation of fibroblasts in combination with mucin deposition in the renal interstitium and glomeruli caused glomerular sclerosis, interstitial fibrosis, atrophic renal tubules, mesangial proliferation, and crescent formation. The pathologic mechanism that

caused the underlying defective fibroblasts that produced mucin may also have caused IgA deposition in the mesangium.

Immunoglobulin A nephropathy, a mesangial proliferative glomerulonephritis characterized by deposition of IgA in the glomerular mesangium, is the most common glomerulonephritis throughout the world.¹⁹ The exact pathogenesis of it remains unclear. Various systemic diseases are associated with IgA nephropathy, such as liver failure, rheumatoid arthritis, and Reiter disease. The role of IgA in IgA nephropathy is uncertain. Waldo²⁰ believes that IgA deposition alone is inadequate to explain the pathogenesis of IgA nephropathy because IgG deposition occurs at the site of complement activation and fixation. The IgA in the aggregate actually inhibits complement activation and prevents effective immune complex clearance. Oortwijn et al²¹ hold the opposite view, that IgA deposition may be one of the initiators of local complement activation in the kidney. We believe that the main cause of nephropathy in our patient was the proliferation of fibroblasts and mucin deposition in the renal interstitium and glomeruli. The IgA deposition in the mesangium may have aggravated it. Because the renal function of our patient was normal, we can easily rule out scleromyxedema-like diseases, such as nephrogenic fibrosing dermopathy or nephrogenic systemic fibrosis, which have been described in patients with stage 4 or 5 chronic kidney disease.²²

Treatment of PM is empirical and usually unsatisfactory. Tacrolimus ointment can be used in topical therapy,²³ and carbon dioxide laser can also be used to clear mild lesions. In this case, prednisone was used to control nephropathy, but it appeared ineffective in controlling either the lesions or the nephropathy. We proposed vaporizing the lesions with a carbon dioxide laser, but the patient declined the treatment because he did not have any cosmetic concerns. The particular eruption pattern of the lesions and kidney involvement are the main points of interest in this case.

Accepted for Publication: December 10, 2010.

Correspondence: Yuping Ran, MD, PhD, Dermatovenereology, West China Hospital, Sichuan University, 37 Guo Xue Xiang, Wang Hou District, Chengdu, People's Republic of China, 610041 (ranyuping@vip.sina.com).

Author Contributions: Dr Ran had full access to all the data in the study and takes responsibility for the integrity of the data and the accuracy of the data analysis. *Study concept and design:* Wang and Ran. *Acquisition of data:* Wang and Yang. *Analysis and interpretation of data:* Wang and Yang. *Drafting of the manuscript:* Wang. *Critical revision of the manuscript for important intellectual content:* Yang and Ran. *Administrative, technical, and material support:* Ran. *Study supervision:* Ran.

Financial Disclosure: None reported.

Funding/Support: This work was partly supported by grant 20050610058 from the Specialized Research Fund for the Doctoral Program of Higher Education.

Additional Contributions: Lin Wang, MD, aided in describing the biopsy specimens. Fengyuan Li, BSMed, aided in performing and analyzing the findings of immunohistochemical staining.

REFERENCES

1. Montgomery H, Underwood LJ. Lichen myxedematosus; differentiation from cutaneous myxedemas or mucoid states. *J Invest Dermatol.* 1953;20(3):213-236.
2. Rongioletti F, Rebora A. Updated classification of papular mucinosis, lichen myxedematosus, and scleromyxedema. *J Am Acad Dermatol.* 2001;44(2):273-281.
3. Borradori L, Aractingi S, Blanc F, Verola O, Dubertret L. Acral persistent papular mucinosis and IgA monoclonal gammopathy: report of a case. *Dermatology.* 1992;185(2):134-136.
4. Chen CW, Tsai TF, Chang SP, Chen YF, Hung CM. Congenital cutaneous mucinosis with spontaneous regression: an atypical cutaneous mucinosis of infancy? *Clin Exp Dermatol.* 2009;34(7):804-807.
5. Coskey RJ, Mehregan A. Papular mucinosis. *Int J Dermatol.* 1977;16(9):741-744.
6. Bragg J, Soldano AC, Latkowski JA. Papular mucinosis (discrete papular lichen myxedematosus). *Dermatol Online J.* 2008;14(5):14.
7. Concheiro J, Pérez-Pérez L, Peteiro C, Labandeira J, Toribio J. Discrete papular lichen myxedematosus: a rare subtype of cutaneous mucinosis. *Clin Exp Dermatol.* 2009;34(8):e608-e610.
8. Redondo Bellón P, Vázquez-Doval J, Idoate M, Quintanilla E. Mucinous nevus. *J Am Acad Dermatol.* 1993;28(5 Pt 1):797-798.
9. Sperber BR, Allee J, James WD. Self-healing papular mucinosis in an adult. *J Am Acad Dermatol.* 2004;50(1):121-123.
10. Wilk M, Schmoedel C. Cutaneous focal mucinosis—a histopathological and immunohistochemical analysis of 11 cases. *J Cutan Pathol.* 1994;21(5):446-452.
11. Terui T, Aiba S, Tagami H. Solitary subcutaneous mucinosis surrounded by bizarre-shaped, factor XIIIa-positive cells with intranuclear vacuoles. *J Cutan Pathol.* 1998;25(5):271-274.
12. Yokoyama E, Muto M. Adult variant of self-healing papular mucinosis in a patient with rheumatoid arthritis: predominant proliferation of dermal dendritic cells expressing CD34 or factor XIIIa in association with dermal deposition of mucin. *J Dermatol.* 2006;33(1):30-35.
13. Cerio R, Griffiths CE, Cooper KD, Nickoloff BJ, Headington JT. Characterization of factor XIIIa positive dermal dendritic cells in normal and inflamed skin. *Br J Dermatol.* 1989;121(4):421-431.
14. Nickoloff BJ. The human progenitor cell antigen (CD34) is localized on endothelial cells, dermal dendritic cells, and perifollicular cells in formalin-fixed normal skin, and on proliferating endothelial cells and stromal spindle-shaped cells in Kaposi's sarcoma. *Arch Dermatol.* 1991;127(4):523-529.
15. Dinneen AM, Dicken CH. Scleromyxedema. *J Am Acad Dermatol.* 1995;33(1):37-43.
16. Truhan AP, Roenigk HH Jr. Lichen myxedematosus: an unusual case with rapid progression and possible internal involvement. *Int J Dermatol.* 1987;26(2):91-95.
17. Pomann JJ, Rudner EJ. Scleromyxedema revisited. *Int J Dermatol.* 2003;42(1):31-35.
18. Peeters P, Praet M, Van Vlem B, Naeyaert JM, Vanholder R. End-stage disease of native kidneys in a patient with biopsy-proven Arndt-Gottron scleromyxedema and recurrence in the transplanted kidney. *Nephrol Dial Transplant.* 2007;22(10):3065-3069.
19. Floege J, Feehally J. IgA nephropathy: recent developments. *J Am Soc Nephrol.* 2000;11(12):2395-2403.
20. Waldo FB. Role of IgA in IgA nephropathy. *J Pediatr.* 1990;116(5):S78-S85.
21. Oortwijn BD, Eijgenraam JW, Rastaldi MP, Roos A, Daha MR, van Kooten C. The role of secretory IgA and complement in IgA nephropathy. *Semin Nephrol.* 2008;28(1):58-65.
22. Mackay-Wiggan JM, Cohen DJ, Hardy MA, Knobler EH, Grossman ME. Nephrogenic fibrosing dermopathy (scleromyxedema-like illness of renal disease). *J Am Acad Dermatol.* 2003;48(1):55-60.
23. Rongioletti F, Zaccaria E, Cozzani E, Parodi A. Treatment of localized lichen myxedematosus of discrete type with tacrolimus ointment. *J Am Acad Dermatol.* 2008;58(3):530-532.