

Cutaneous horn: a potentially malignant entity

N. F. Fernandes, S. Sinha, W. C. Lambert, and R. A. Schwartz

S U M M A R Y

A cutaneous horn is a conical, dense, hyperkeratotic protrusion that often appears similar to the horn of an animal. It is a morphologic designation referring to an unusually cohesive keratinized material, not a true pathologic diagnosis. Cutaneous horns occur in association with, or as a response to, a wide variety of underlying benign, pre-malignant, and malignant cutaneous diseases. The most important common concern is distinguishing a hyperkeratotic actinic keratosis from a cutaneous squamous cell carcinoma. Keratoacanthoma is another cause, as illustrated herein as a projective cutaneous tumor with a fingernail-like appearance. The treatment of choice for cutaneous horns is shave excision with subsequent histopathologic evaluation to rule out underlying malignancy and to guide potential further therapy.

K E Y W O R D S

**cutaneous
horn, cornu
cutaneum,
hyperkerato-
sis, actinic
keratosis,
keratoacantho-
ma, squamous
cell
carcinoma,
Kaposi's
sarcoma**

Introduction

A cutaneous horn is a conical, dense hyperkeratotic protrusion that often resembles the horn of an animal. The earliest documented case of cutaneous horn, or cornu cutaneum, was that of an elderly Welsh woman in London who was displayed commercially as an anomaly of nature in 1588 (1). There were several other accounts of cutaneous horns in the sixteenth and seventeenth centuries, including those described by Danish anatomist Thomas Bartholin in 1670. Illustrations from that time portray these growths as grotesque, and numerous natural and supernatural theories arose regarding their etiology. The London surgeons Everard Home and his brother-in-law John Hunter are generally credited

with the characterization of cutaneous horns as a medical disorder in the late eighteenth century (2).

Epidemiology and etiology

Cutaneous horns are nodules composed of compact keratin that project above the surface of the skin. They differ from animal horns by the absence of a central bone. Cutaneous horns are rare; no incidence or prevalence has been reported. They occur most commonly in light-skinned patients 50 years or older. The condition is thought to be more frequent in men, but no consistent sex pattern has been demonstrated (3).

The term "cutaneous horn" is a morphologic designation referring to unusually cohesive

keratinized material, not a true pathologic diagnosis (4). The reason for this impressive retention of keratin is unknown. The significance of cutaneous horns is that they occur in association with, or as a response to, a wide variety of underlying benign, pre-malignant, and malignant cutaneous diseases. These conditions include actinic keratosis, squamous cell carcinoma, seborrheic keratosis, molluscum contagiosum, verruca vulgaris, trichilemmoma, Bowen's disease, and basal cell carcinoma (5–11).

Clinical features

Cutaneous horns are generally evident as elongated, keratinous, white or yellowish projections that range from a few millimeters to several centimeters in size (12–13). As Kaposi (14) thoroughly described them over a century ago, they can be variable in size and form, such as cylindrical, conical, pointed, corrugated transversely and longitudinally, or curved like a ram's horn. They are solitary, growing slowly over years to decades if left alone (13, 15, 16). They are rarely seen greater than 1 cm in length in clinical practice due to their slow-growing nature and early removal. Growth may also be disrupted by trauma. However, cutaneous horns as long as 25 cm have been described (16). The base of the horn may be flat, nodular, or crateriform (12). Surrounding inflammation and an infiltrated base are unusual, but they may indicate malignancy if present (15). Tenderness at the base also favors malignancy (12). Cutaneous horns may be confused with conditions such as ectopic nail (17), which the cutaneous horn on the back of a 92-year-old African-American man shown here strongly resembled (Figure 1).

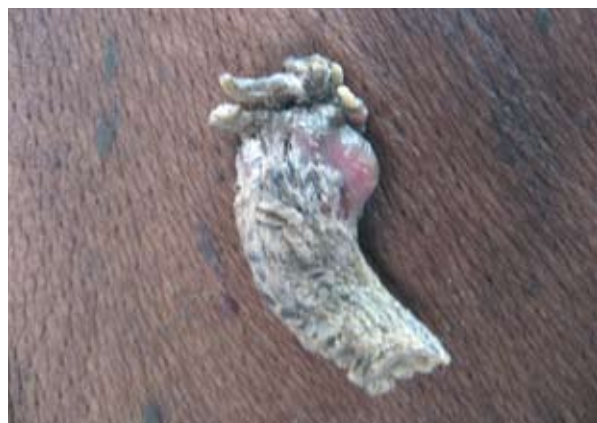

Fig. 1. Cutaneous horn on the back resembling a fingernail; a yellowish-whitish, curved 4 cm protrusion, representing a keratoacanthoma.

Approximately 30% of cutaneous horns are found on the upper face and scalp (1). Other common locations include sun-exposed areas such as the ear, lip, chest, neck, and shoulder (3). They may, however, develop on areas not exposed to sunlight such as the penis, mucosal lower lip, and nasal vestibule (18, 19).

Cutaneous horns themselves are composed of dead keratin, but special attention must be paid to their bases for underlying conditions that may be benign, pre-malignant, or frankly malignant. In elderly, light-skinned people, they most often represent pre-malignant hypertrophic actinic keratoses (13, 20). Other diseases such as nevus sebaceous of Jadassohn, metastatic renal cell carcinoma, sebaceous carcinoma, dermatofibroma, Paget's disease of the breast, papillary eccrine adenoma, pyogenic granuloma, Kaposi's sarcoma, prurigo nodularis, and keratoacanthoma have also been found at the base of cutaneous horns (7, 21–30). Risk factors for underlying malignancy include advanced age, male sex, large base or height-to-base ratio, and presence on a sun-exposed location (4). A pre-malignant or malignant base is also more likely to occur in patients with a history of actinic keratosis or skin cancer (6).

Histopathology

The mass of the cutaneous horn usually shows compact, diffuse hyperkeratosis with parakeratosis (Fig. 2). Occasionally the hyperkeratosis may be

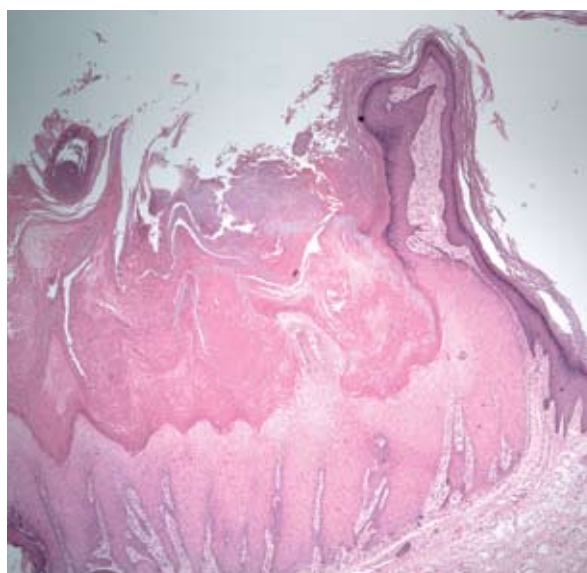


Fig. 2. Cutaneous horn shown above; a keratoacanthoma with typical hyperkeratosis with associated parakeratosis, overlying a keratoacanthoma (hematoxylin-eosin $\times 100$).

orthokeratotic in nature. The granular layer may be visible underneath, with variable acanthosis present as well (13). Findings at this neoplasm’s base will vary based on the underlying process. Of special importance are identification of pre-malignant actinic (or arsenical) keratosis, malignant squamous cell carcinoma, and sometimes keratoacanthoma (21, 27, 30). The latter was found in the patient discussed here.

Management

As Kaposi (14) noted more than a century ago, cutaneous horns can be removed by simple detachment and cauterization of the papillary base. However, we favor a shave excision, being sure to obtain a good specimen from the base of the cutaneous horn for dermatopathologic evaluation. Cryosurgery may be used as an alternative treatment, although we do not recommend it because it does not preserve the specimen for histopathology (4).

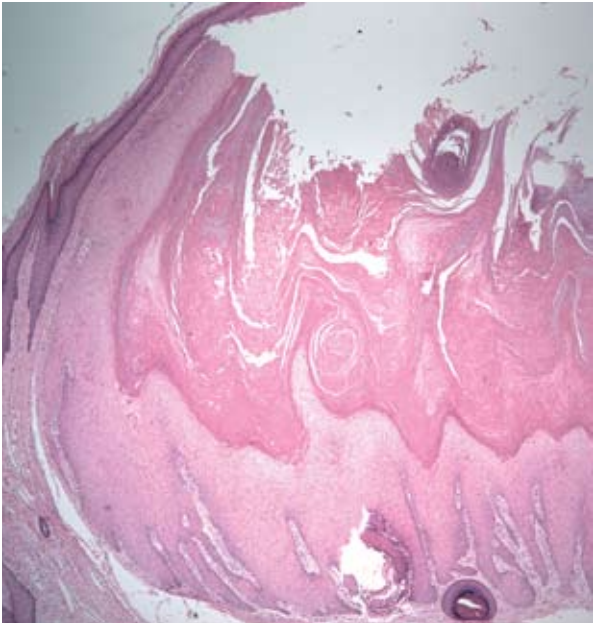


Fig. 3. Edge of the keratoacanthoma, at the base of the cutaneous horn, with proliferating squamous epithelial cells (hematoxylin-eosin ×100).

Table 1. Causes of cutaneous horns.

Causes of cutaneous horns	
Most common causes	Other causes
Actinic keratosis	Bowen’s disease
Seborrheic keratosis	Benign fibroma
Verruca vulgaris	Basal cell epithelioma
Squamous cell carcinoma	Dermatofibroma
Molluscum contagiosum	Keratoacanthoma
	Pyogenic granuloma
	Angiokeratoma
	Benign lichenoid keratosis
	Epidermal cyst
	Epidermolytic acanthoma
	Kaposi’s sarcoma
	Sebaceous adenoma
	Trichilemmoma
	Verrucous epidermal nevus

REFERENCES

1. Bondeson J. Everard Home, John Hunter and cutaneous horns: a historical review. *Am J Dermatopathol*. 2001;23:362–9.
2. Home E. Observations on certain horny excrescences of the human body. *Philos Trans R Soc Lond B Biol Sci*. 1791;81:95–105.
3. Copcu E, Sivrioglu N, Culhaci N. Cutaneous horns: are these lesions as innocent as they seem to be? *World J Surg Oncol*. 2004;2:18.
4. Fox GN. Facial lesion that came “out of nowhere.” *J Fam Pract*. 2004;53:779–81.
5. Akan M, Yıldırım S, Avcı G, Aköz T. Xeroderma pigmentosum with a giant cutaneous horn. *Ann Plast Surg*. 2001;46:665–6.
6. Bart RS, Andrade R, Kopf AW. Cutaneous horns. A clinical and histopathologic study. *Acta Derm Venereol (Stockh)* 1968;48:507–15.
7. Findlay RF, Lapins NA. Pyogenic granuloma simulating a cutaneous horn. *Cutis*. 1983;31:610–2.
8. Schosser RH, Hodge SJ, Gaba CR, Owen LG. Cutaneous horns: a histopathologic study. *South Med J*. 1979;72:1129–31.
9. Baruchin A, Sagi A, Lupo L, Hauben D. Cutaneous horn (cornu cutaneum). *Int J Tissue React*. 1984;6:355–7.
10. Wiederkehr M, Schwartz RA. Giant proliferative molluscum contagiosum. *Acta Dermatovenereol Alp Panonica Adriat*. 2002;11:101–4.
11. Brown J, Janniger CK, Schwartz RA, Silverberg NB. Childhood molluscum contagiosum. *Int J Dermatol*. 2006;45:93–9.
12. Tauro LF, Martis JJS, John SK, Kumar KP. Cornu cutaneum at an unusual site. *Indian J Plast Surg* 2006;39:76–8.
13. Schwartz RA, Stoll HL, Jr. Epithelial precancerous lesions. In: Freedberg I, Eisen AZ, Wolff K, Austen KF, Goldsmith LA, Katz SI, Fitzpatrick TB, editors. *Fitzpatrick's dermatology in general medicine*. New York: McGraw-Hill; 1999. p. 823–39.
14. Kaposi M. Pathology and treatment of diseases of the skin for practitioners and students. Translation of the last German edition under the supervision of James C. Johnston, M.D. New York: William Wood & Company; 1895, pages 432–433.
15. Kastanioudakis I, Skevas A, Assimakopoulos D, Daneilidis B. Cutaneous horn of the auricle. *Otolaryngol Head Neck Surg*. 1998;118:735.
16. Michal M, Bisceglia M, Di Mattia A, Requena L, Fanburg-Smith JC, Mukensnabl P, Hes O, Cada F. Gigantic cutaneous horns of the scalp: lesions with a gross similarity to the horns of animals: a report of four cases. *Am J Surg Pathol*. 2002;26:789–94.
17. Narang T, Kanwar AJ. Ectopic nail with polydactyly. *J Am Acad Dermatol*. 2005;53:1092–3.
18. Rekha A, Ravi A. Cornu cutaneum-cutaneous horn on the penis. *Indian J Surg*. 2004;66:296–7.
19. Mutaf M. A rare perioral lesion: cutaneous horn of the lower lip. *Eur J Plast Surg*. 2007;29:339–41.
20. Schwartz RA, Bridges TM, Butani AK, Ehrlich A. Actinic keratosis: an occupational and environmental disorder. *J Eur Acad Dermatol Venereol*. 2008;22:606–15.
21. Schwartz RA. Keratoacanthoma. *J Am Acad Dermatol*. 1994;30:1–19.
22. Arvas L, Livaoğlu M, Karaçal N, Sözen E, Kara B. Giant cutaneous horn with naevus sebaceus. *J Plast Reconstr Aesthet Surg*. 2007;60:1268–9.
23. Öztürk S, Çil Y, Şengezer M, Yiğit T, Eski M, Özcan A. Squamous cell carcinoma arising in the giant cutaneous horns accompanied with renal cell carcinoma. *Eur J Plast Surg*. 2006;28:483–5.

24. Kitagawa H, Mizuno M, Nakamura Y, Kurokawa I, Mizutani H. Cutaneous horn can be a clinical manifestation of underlying sebaceous carcinoma. *Br J Dermatol*. 2007;156:180–2.
25. Kim YJ, Jeon J, Son SW, Kim AR, Oh CH, Song HJ. Dermatofibroma: unusual lesion with underlying cutaneous horn. *Korean J Dermatol*. 2006;44:754–6.
26. Dabski K, Stoll HL, Jr. Paget's disease of the breast presenting as a cutaneous horn. *J Surg Oncol*. 1985;29:237–9.
27. Schwartz RA. Keratoacanthoma: an abortive squamous cell carcinoma that does not always have to fail. *G Ital Dermatol Venereol*. 2003;138:355–62.
28. Blasini W, Hu S, Gugic D, Vincek V. Papillary eccrine adenoma in association with cutaneous horn. *Am J Clin Dermatol*. 2007;8:179–82.
29. Khaitan BK, Bajaj N, Berma KK. Cutaneous horn in a lesion of prurigo nodularis. *Acta Derm Venereol*. (Stockh) 1996;76:85–6.
30. Schwartz RA. Keratoacanthoma: a clinico-pathologic enigma. *Dermatol Surg*. 2004;30:326–33.

**A U T O R S '
A D D R E S S E S**

Neil F. Fernandes, MD, Dermatology and Pathology, New Jersey Medical School, 185 South Orange Avenue, Newark, NJ, 07103

Smeeta Sinha, MD, same address

W. Clark Lambert, MD, PhD, same address

Robert A. Schwartz, MD, MPH, Dermatology and Pathology, New Jersey Medical School, 185 South Orange Avenue, Newark, NJ 07103, corresponding author, E-mail: roschwar@cal.berkeley.edu