Dermatologic Therapy, Vol. 22, 2009, 85–89
Printed in the United States · All rights reserved

© 2009 Wiley Periodicals, Inc.
DERMATOLOGIC THERAPY
ISSN 1396-0296

HOT TOPICS

Palmoplantar pustulosis treated with itraconazole: a single, active-arm pilot study

M. T. V'lckova-Laskoska, N. G. Caca-Biljanovska, D. S. Laskoski, & S. J. Kamberova
Department of Dermatology, School of Medicine, University Sts. Cyrilus and Methodius, Skopje, Macedonia

ABSTRACT: Pustulosis palmoplantaris (PPP; synonyms: pustulosis palmaris et plantaris, palmoplantar amicrobic pustulosis) is a common chronic, relapsing, pustular eruption affecting the palms and soles. The authors report the successful treatment of six therapy-experienced patients with histologically confirmed PPP with oral itraconazole (100 mg/day for 1 month, followed by a month of 100 mg/day every other day). Three of six patients showed complete clearance of pustules, significant reduction of erythema, and unnoticeable desquamation, whereas the other three patients had no new pustules appearing and had modest reduction of erythema and desquamation. All patients experienced relapses within a month of therapy cessation. Two of the three complete responders reinitiated itraconazole therapy at 100 mg/day for another 2 weeks, followed by a maintenance dose of 50 mg/day until achieving remission. As complete responses are not commonly observed in placebo treatments in placebo-controlled trials for PPP, the authors believe that the present study shows that itraconazole is an effective treatment for treatment-resistant PPP.

KEYWORDS: itraconazole, palmoplantar amicrobic pustulosis, palmoplantar pustulosis, palmoplantar pustular psoriasis, pustulosis palmaris et plantaris

Introduction

Palmoplantar pustulosis (PPP; synonyms: pustulosis palmaris et plantaris, palmoplantar amicrobic pustulosis) is a chronic inflammatory skin condition characterized by recurrent crops of yellowish sterile pustules, erythema, and desquamation on the palms and soles. The pustules are usually ~5 mm in diameter and several stages of pustules (starting with yellow, then green, and finally "dried up" brown) are present concurrently. PPP is also known as chronic palmoplantar pustular psoriasis as it is considered by some to be a variant of psoriasis vulgaris. However, most PPP patients have no evidence of psoriasis elsewhere, and no link has been found between PPP and the major susceptibility locus for psoriasis or the tumor necrosis factor alpha (TNF-α) promoter polymorphisms associated with psoriasis vulgaris (1,2).

On average, most PPP patients are women and at least 50 years of age at the time of the occurrence of the first symptoms. The disease runs a prolonged course, with intermittent exacerbations followed by partial but rarely complete remissions. A burning feeling, intolerable itch, and cracking may further increase discomfort.

Conflict of interest: None.
Address correspondence to: Marija T. V'lckova-Laskoska, MD, PhD, Pirinska 40, 1000 Skopje, Macedonia, or email: lasko@lasko.com.mk.

资料来自互联网，仅供科研和教学使用，使用者请于24小时内自行删除

FIG. 1. (a) Typical clinical features of PPP on the soles and palmsbeforeitraconazole treatment. (b) Complete clearance of the lesions by the end of the 2-monthitraconazole treatment.

PPP has been associated with arthritis of the anterior thorax (3), thyroid abnormalities (4,5), decreased bone mineral density (6,7), *Helicobacter pylori* infection (8), and smoking (5–7). Interestingly, neither smoking cessation nor thyroxine substitution in hypothyroid patients led to an improvement in PPP symptoms (5,7); however, recently, a complete remission of palmoplantar psoriasis through *H. pylori* eradication has been reported (9). Finally, a small study showed that anxiety scores were higher in PPP patients than in controls, arguing that stress and exacerbations of PPP may be related (10).

Numerous therapeutic options (steroids, retinoids, dapsone, methotrexate, colchicines, cyclosporine, and photochemotherapy) usually do not give satisfactory results or are frequently ineffective.

Histologically, PPP is characterized by local over-expression of inflammatory mediators (11,12) and, consequently, infiltration of different types of inflammatory cells (13). Itraconazole, a broad-spectrum antifungal triazole, has also shown in vitro anti-inflammatory activity (14,15) and anecdotal activity for the treatment of PPP (16). Therefore, the authors set out to assess the clinical potential of itraconazole for the management of PPP in treatment-experienced patients.

Report

The aim of the present study was to assess the effects of itraconazole on symptom relief in treatment-experienced PPP patients. The inclusion criteria were (i) actively pustulating skin lesions and (ii) disease duration of at least 6 months. Exclusion criteria were (i) no signs of psoriasis elsewhere and (ii) no ongoing medication regimen with systemic corticosteroids, cytostatics, retinoids, or psoralen plus ultraviolet A radiation (PUVA) therapy.

Six female patients with persistent PPP were treated with oral itraconazole. The patients ranged in age from 39 to 57 years at the start of therapy. Disease duration prior to therapy ranged from 8 months to 12 years. With respect to the most common medical conditions associated with PPP referenced in the introduction, none of the patients reported pain and/or swelling of joints or bones in the anterior chest wall, and all six patients had normal thyroid test results, negative *H. pylori* antibody tests, and normal bone mineral density. However, three of the six patients were heavy smokers.

All patients presented with typical clinical features of PPP: sterile, yellow pustules evolving into dusky red crusts, erythema, and desquamation on the palms and soles (FIGS. 1a, 2a, 3a). In addition, the diagnosis was histologically confirmed in all six patients. Specifically, biopsies from all six patients showed a characteristic histopathologic picture of "sterile" spongiform pustule. Histologically, there was a network of cell remnants in the upper layers of the epidermis with neutrophilic leukocytes enmeshed in the network – a typical picture of the spongiform pustule of Kogoj. Variably dense lymphohistiocytic infiltrate with some neutrophils was found around the dilated vessels of the upper dermis. Periodic acid-Schiff staining was

资料来自互联网，仅供科研和教学使用，使用者请于24小时内自行删除

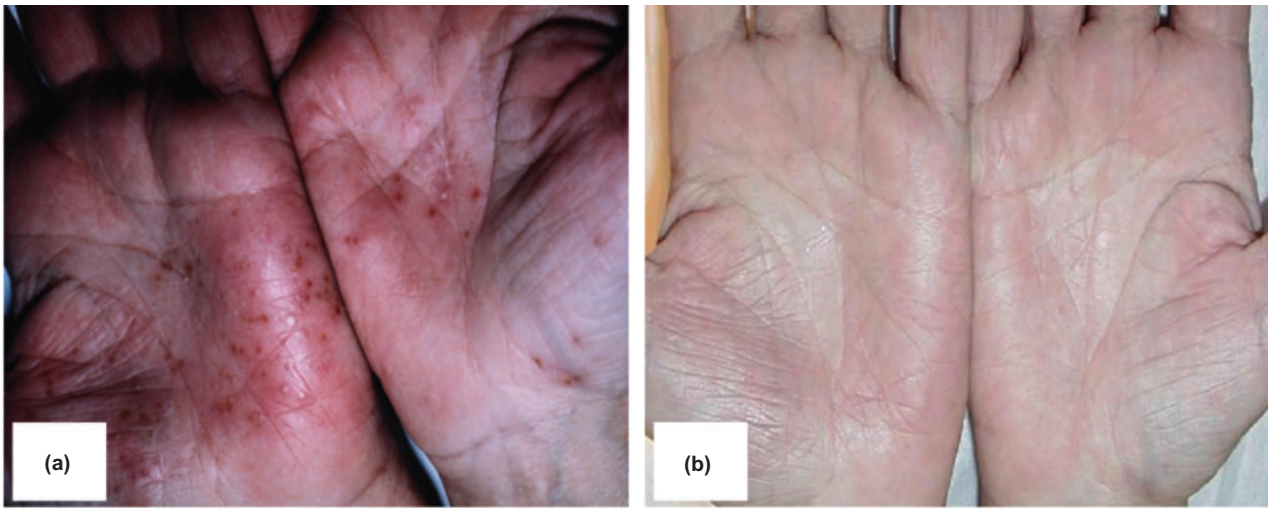

FIG. 2. **(a) Typical clinical features of PPP on the soles and palms before itraconazole treatment. (b) Complete clearance of the lesions by the end of the 2-monthitraconazole treatment.**

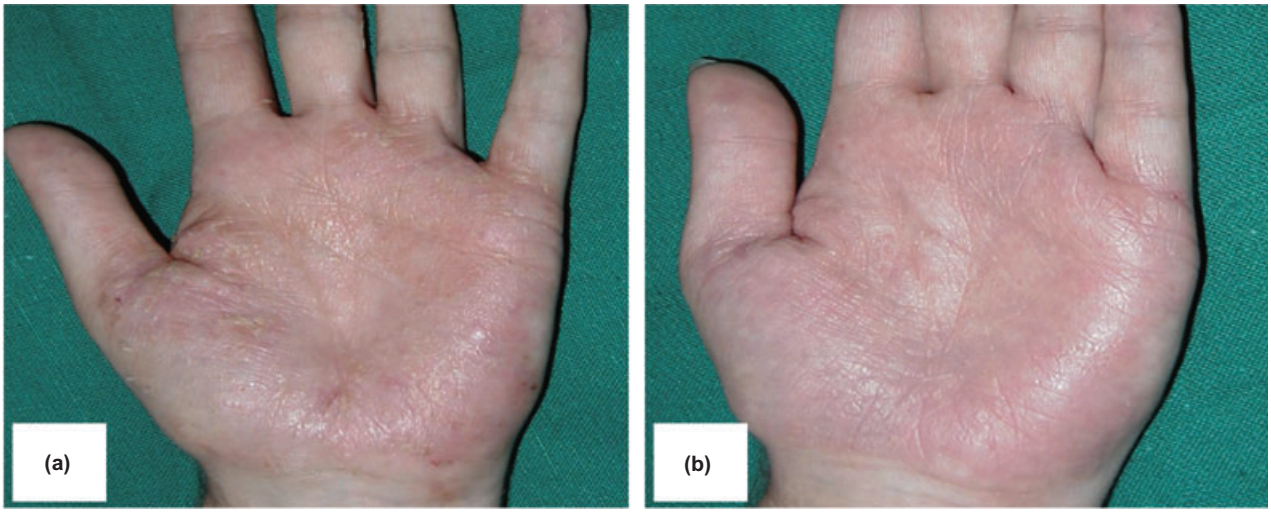

FIG. 3. **(a) Typical clinical features of PPP on the soles and palms before itraconazole treatment. (b) Complete clearance of the lesions by the end of the 2-monthitraconazole treatment.**

performed in all histologic preparations and as no mycotic elements were seen, dermatophytosis was excluded.

Finally, no hyphae were detected on KOH preparations.

All patients were treated with 100 mg/day oral itraconazole for 2 months. Initial treatment was 100 mg/day for 4 weeks, and for the next 4 weeks, 100 mg every other day. The effects of the treatment were evaluated after 1, 2, and 3 months of therapy initiation. In addition, tests for blood biochemical markers, as well as kidney and liver function, were performed at each time point of efficacy evaluation. Finally, all patients were surveyed for potential subjectively reported side effects (gastrointestinal disturbances, neuralgias, etc.).

Three of the six patients showed complete clearance of pustules, significant reduction of erythema, and unnoticeable desquamation by the end of the 2-month treatment regimen (FIGS. 1b, 2b, 3b), whereas the other three patients had no new pustules appearing, modest reduction of erythema, and reduced desquamation. In all patients, no new pustules formed within 2 weeks of therapy initiation. All patients experienced relapses within a month of completing therapy. Two of the three complete responders reinitiated itraconazole therapy at 100 mg/day for another 2 weeks, followed by a maintenance dose of 50 mg/day until achieving remission.

With respect to treatment safety, no effects on blood biochemical markers, as well as kidney and

资料来自互联网，仅供科研和教学使用，使用者请于24小时内自行删除

liver functions, were observed. Finally, no adverse events were reported.

Discussion

PPP is a common, chronic, relapsing, pustular eruption affecting the palms and soles. The therapy for PPP is largely unsatisfactory. Although several studies have been performed testing different therapies for PPP, the heterogeneity in both the assessment of disease severity and outcome measurements makes pooling and comparison of statistical data difficult. Of topical therapies, only corticosteroids under hydrocolloid occlusion have shown evidence of efficacy in PPP in randomized clinical trials (17). Topical PUVA holds little promise as effective therapy for PPP (18). Grenz ray (low-voltage X-ray) therapy has shown evidence of improvement, but not of clearance, in PPP patients (19). Both systemic photochemotherapy (20,21) and retinoids (22–24) are of great value for PPP. However, many patients who do improve will either have an insufficient response or have to terminate retinoid-based therapy because of retinoid side effects. Finally, cyclosporine and tetracycline have also shown some, yet limited, value for the treatment of PPP (reviewed in (25)).

PPP is characterized by numerous infiltrating mast cells, eosinophils, and T lymphocytes in the papillary dermis, in addition to the accumulation of neutrophils and eosinophils in the pustules (13). Chemotactic factors, such as interleukin-8 (IL-8) and C5a/C5a des Arg (11,12), are produced by the epidermal keratinocytes and complement, respectively, in the epidermal lesions of PPP (26). Itraconazole, a broad-spectrum antifungal triazole, has also shown anti-inflammatory activity. In particular, itraconazole inhibits chemotaxis of neutrophils, the production of IL-8 and synthesis of pro-inflammatory metabolites (i.e., 5-lipoxygenase) (14,15). Furthermore, itraconazole has shown anecdotal activity for the treatment of PPP (16). Given the involvement of inflammatory mediators in PPP, the anti-inflammatory activity of itraconazole, and one prior report of activity in PPP, the authors set out to test the efficacy of itraconazole in six patients with therapy-resistant PPP. The authors report the successful treatment of six treatment-experienced patients with histologically confirmed PPP with oral itraconazole (100 mg/day for 2 months).

Conclusion

Here the authors report significant reduction in the frequency of pustular eruptions, the number of pustules, and the severity of erythema and desquamation with tolerable doses (100 mg/day) of oral itraconazole for 2 months. The findings were in line with prior experience by others (16). Despite the fact that this was not a placebo-controlled study, the authors think that the fact that three of the six patients reached complete response is highly indicative of the activity of itraconazole in PPP as complete responses have not been observed in a recent review of 23 placebo-controlled trials for PPP treatments (25). Therefore, the authors recommend oral itraconazole for the management and treatment of PPP.

References

1. Asumalahti K, Veal C, Laitinen T, Suomela S, Allen M, Elomaa O, et al. Coding haplotype analysis supports HCR as the putative susceptibility gene for psoriasis at the MHC PSORS1 locus. Hum Mol Genet 2002: **11** (5): 589–597.
2. Mossner R, Kingo K, Kleensang A, Krüger U, König IR, Silm H, et al. Association of TNF -238 and -308 promoter polymorphisms with psoriasis vulgaris and psoriatic arthritis but not with pustulosis palmoplantaris. J Invest Dermatol 2005: **124** (1): 282–284.
3. Edlund E, Johnsson U, Lidgren L, Pettersson H, Sturfelt G, Svensson B, et al. Palmoplantar pustulosis and sternocostoclavicular arthro-osteitis. Ann Rheum Dis 1988: **47** (10): 809–815.
4. Rosen K, Mobacken H, Nilsson LA. Increased prevalence of antithyroid antibodies and thyroid diseases in pustulosis palmoplantaris. Acta Derm Venereol 1981: **61** (3): 237–240.
5. Rosen K, Lindstedt G, Mobacken H, Nystrom E. Thyroid function in patients with pustulosis palmoplantaris. J Am Acad Dermatol 1988: **19** (6): 1009–1016.
6. Nymann P, Kollerup G, Jemec GBE, Grossmann E. Decreased bone mineral density in patients with pustulosis palmaris et plantaris. Dermatology 1996: **192** (4): 307–311.
7. O'Doherty CJ, MacIntyre C. Palmoplantar pustulosis and smoking. BMJ (Clinical Research Ed) 1985: **291** (6499): 861–864.
8. Saez-Rodriguez M, Noda-Cabrera A, Garcia-Bustinduy M, Gulmera-Martin-Neda F, Dorta-Alom S, Escoda-Garcia M, et al. Palmoplantar pustulosis associated with gastric *Helicobacter pylori* infection. Clin Exp Dermatol 2002: **27** (8): 720.
9. Hubner AM, Tenbaum SP. Complete remission of palmoplantar psoriasis through Helicobacter pylori eradication: a case report. Clin Exp Dermatol 2008: **33** (3): 339–340.
10. Saez-Rodriguez M, Noda-Cabrera A, Alvarez-Tejera S, Gulmera-Martin-Neda F, Dorta-Alom S, Escoda-Garcia M, et al. The role of psychological factors in palmoplantar pustulosis. J Eur Acad Dermatol Venereol 2002: **16** (4): 325–327.
11. Takematsu H, Isono N, Kato T, Tagami H. Normal human epidermal keratinocyte-derived neutrophil chemotactic factor. Tohoku J Exp Med 1990: **162** (1): 1–13.
12. Takematsu H, Tagami H. Quantification of chemotactic peptides (C5a anaphylatoxin and IL-8) in psoriatic lesional skin. Arch Dermatol 1993: **129** (1): 74–80.
13. Eriksson MO, Hagforsen E, Lundin IP, Michaelsson G. Palmoplantar pustulosis: a clinical and immunohistological study. Br J Dermatol 1998: **138** (3): 390–398.

资料来自互联网，仅供科研和教学使用，使用者请于24小时内自行删除

14. Steinhilber D, Jaschonek K, Knospe J, Morof O, Roth HJ. Effects of novel antifungal azole derivatives on the 5-lipoxygenase and cyclooxygenase pathway. Arzneimittelforschung 1990: **40** (11): 1260–1263.
15. Vuddhakul V, Mai GT, McCormack JG, Seow WK, Thong YH. Suppression of neutrophil and lymphoproliferative responses in vitro by itraconazole but not fluconazole. Int J Immunopharmacol 1990: **12** (6): 639–645.
16. Mihara M, Hagari Y, Morimura T, Nakayama H, Isihara M, Aki T, et al. Itraconazole as a new treatment for pustulosis palmaris et plantaris. Arch Dermatol 1998: **134** (5): 639–640.
17. Kragballe K, Larsen FG. A hydrocolloid occlusive dressing plus triamcinolone acetonide cream is superior to clobetasol cream in palmo-plantar pustulosis. Acta Derm Venereol 1991: **71** (6): 540–542.
18. Layton AM, Sheehan-Dare R, Cunliffe WJ. A double-blind, placebo-controlled trial of topical PUVA in persistent palmoplantar pustulosis. Br J Dermatol 1991: **124** (6): 581–584.
19. Lindelof B, Beitner H. The effect of grenz ray therapy on pustulosis palmoplantaris. A double-blind bilateral trial. Acta Derm Venereol 1990: **70** (6): 529–531.
20. Murray D, Corbett MF, Warin AP. A controlled trial of photochemotherapy for persistent palmoplantar pustulosis. Br J Dermatol 1980: **102** (6): 659–663.
21. Rosen K, Mobacken H, Swanbeck G. PUVA, etretinate, and PUVA-etretinate therapy for pustulosis palmoplantaris. A placebo-controlled comparative trial. Arch Dermatol 1987: **123** (7): 885–889.
22. Foged E, Holm P, Larsen PO. A randomized trial of etretinate (Tigason) in palmoplantar pustulosis. Dermatologica 1983: **166** (4): 220–223.
23. White SI, Marks JM, Shuster S. Etretinate in pustular psoriasis of palms and soles. Br J Dermatol 1985: **113** (5): 581–585.
24. White SI, Puttick L, Marks JM. Low-dose etretinate in the maintenance of remission of palmoplantar pustular psoriasis. Br J Dermatol 1986: **115** (5): 577–582.
25. Marsland AM, Chalmers RJ, Hollis S, Leonardi-Bee J, Griffiths CE. Interventions for chronic palmoplantar pustulosis. Cochrane Database Syst Rev 2006: CD001433.
26. Uehara M, Ofuji S. The morphogenesis of pustulosis palmaris et plantaris. Arch Dermatol 1974: **109** (4): 518–520.

资料来自互联网，仅供科研和教学使用，使用者请于24小时内自行删除

Copyright of Dermatologic Therapy is the property of Blackwell Publishing Limited and its content may not be copied or emailed to multiple sites or posted to a listserv without the copyright holder's express written permission. However, users may print, download, or email articles for individual use.