CED
Clinical and Experimental Dermatology

Efficacy of low-dose methotrexate in the treatment of dermatomyositis skin lesions

T. Hornung, A. Ko, T. Tüting, T. Bieber and J. Wenzel

Department of Dermatology and Allergy, University of Bonn, Bonn, Germany

doi:10.1111/j.1365-2230.2011.04188.x

Summary

A limited number of case series has indicated that methotrexate (MTX) might be a useful drug in the treatment of dermatomyositis (DM), a rare autoimmune disease involving the skin and muscles. However, these earlier studies mainly focused on the efficacy of MTX on DM muscular symptoms. To analyse the efficacy of MTX on skin lesions in DM, the records of 34 patients with DM seen between 2004 and 2009 were retrospectively analysed, and the DM skin disease activity at different time points was determined, with specific focus on cutaneous features using the validated Cutaneous Dermatomyositis Activity Index (CDASI) score. The lesional inflammation was scored in primary skin biopsies. Additionally, we performed a systematic review of the available literature. In our series, 11 patients with DM received MTX, and in 8 of them, MTX led to a significant reduction of the DM skin lesions. CDASI scores decreased from 15.7 to 6.4 ($P < 0.01$) within 2–3 months, supporting the effectiveness of MTX in skin disease in DM. The lymphocytic infiltrate in primary skin lesions of MTX responders was significantly more pronounced than that in nonresponders. These results indicate that MTX might be an effective drug to treat the cutaneous symptoms of DM, as measured by the validated CDASI. Interestingly, MTX responders histologically presented a significantly stronger lesional lymphocytic inflammatory infiltrate than did nonresponders. These findings suggest that the functional inhibition of lymphocyte migration in the skin might be an important mechanism of MTX in the treatment of DM.

DM is an autoimmune connective tissue disease affecting both skin and muscles. It is characterized by heliotrope erythema of the face, erythematous papules at the tensor sides of the fingers (Gottron sign), and macular erythema in sun-exposed skin areas. Other clinical findings include proximal muscle weakness and increased serum levels of creatinine kinase. The clinical symptoms are very variable, ranging from localized skin lesions to life-threatening systemic disease. Patients not meeting the original Bohan and Peter criteria[1] can still be diagnosed with DM based on these pathognomic skin changes. There is no histopathological proof of DM in skin lesions. The full spectrum and criteria have been detailed and classified by Euwer *et al.*[2]

Systemic corticosteroids are the established first-line treatment for DM; however, their long-term use is limited because of the known side-effects. Consequently, steroid-sparing immunosuppressive drugs, including azathioprine, methotrexate (MTX), ciclosporin A and cyclophosphamide, were introduced for treatment of DM. In our practice, MTX is most commonly used. However, its use in DM is based on a limited number of published case reports and case series, and only one open study. Skin-specific outcomes are rarely reported (Table 1). Furthermore, these earlier studies focused on muscle disease in DM, but reliable data on skin disease are missing. Because the skin may be the most severely affected organ in DM and may fail therapeutic

Correspondence: Thorsten Hornung, Department of Dermatology, University of Bonn, Sigmund-Freud-Strasse 25, 53105 Bonn, Germany
E-mail: thorsten.hornung@ukb.uni-bonn.de

Conflict of interest: none declared.

Accepted for publication 1 June 2011

© The Author(s)
CED © 2011 British Association of Dermatologists

资料来自互联网，仅供科研和教学使用，使用者请于24小时内自行删除

Table 1 Methotrexate and dermatomyositis: overview of the literature published between 1968 and 2010 reporting skin-specific outcomes.

Year	First author	Journal	Type of study	Focus	Muscle parameters	Skin parameters
1968	Malaviya	*Lancet*	Case series (*n* = 4)	Muscle >> skin	ESR, aldolase	Descriptive*
1971	Arnett	*Ann Rheum Dis*	Case series (*n* = 10)	Muscle >> skin	CK, aldolase, LDH	Descriptive*
1983	Callen	*J Surg Oncol*	Case report (*n* = 1)	Muscle > skin	CK, muscle biopsy	Descriptive*
1995	Zieglschmid-Adams	*J Am Acad Dermatol*	Case series (*n* = 10)	Muscle = skin	Descriptive	Descriptive*
1996	Abernethy M.I.	*Dermatology*	Case report (*n* = 1)	Ectropion	CK, aldolase	Descriptive*
1997	Kasteler	*J Am Acad Dermatol*	Retrospective review (*n* = 13)	Skin	None	Semiquantitative scale

CK, creatinine kinase; ESR, erythrocyte sedimentation rate; LDH, lactate dehydrogenase. *Descriptive was defined as qualitative description of clinical findings.

Table 2 Summary of clinical data for patients with dermatomyositis (DM) and treatment results with low-dose weekly methotrexate (MTX).

					Baseline			Post-treatment			
Patient no	DM type	Gender	Age, years	Previous therapies	CDASI	CK, U/L	Pred dose, mg/day	Pred mg/day	MTX, mg/week	CDASI	CK, U/L
1	II	F	66	Pred	8	513	60	0	15	5	131
2*	VI	F	84	Pred	14	NP	10	10	15	10	NP
3	II	F	68	Pred	14	1112	60	5	7.5	2	102
4	V	F	70	Pred	14	NP	10	6	7.5	0	NP
5	VI	F	46	Pred	12	NP	40	15	15	0	NP
6	VI	F	60	Pred	21	NP	20	10	15	9	NP
7	III	M	69	Pred	15	368	0	0	15	7	121
8	VI	M	64	Mycophenolic acid	13	NP	60	20	20	3	NP
9*	III	F	81	Pred, azathioprine	4	NP	60†	15	15	4	NP
10*	VI	M	47	Pred	17	NP	40	10	15	14	NP
11	II	F	49	Pred, azathioprine	23	1113	80	15	15	6	218
Mean	–	–	64	–	14.1	776.5	40	9.64	14.91	5.75	143

CDASI, Cutaneous Dermatomyositis Activity Index; CK, creatine kinase; NP, nonpathological; Pred, prednisone. *Non-responders; †only for 3 days before MTX then reduced to 15 mg.

intervention even if muscles respond well,[3] we decided to analyse our DM patient data, focusing on the efficacy of MTX on the cutaneous symptoms of DM.

Methods

Patient selection and classification

We retrospectively reviewed the records of all patients with DM seen at our outpatient care unit for cutaneous autoimmune diseases between 2005 and 2009. Type and extent of disease, laboratory parameters, concomitant medication and side-effects were carefully recorded at the time of presentation and during follow-up.

In total, 34 individual patients with proven DM presented to our autoimmune outpatient unit between 2005 and 2009. Of these, 11 received MTX treatment (8 women/3 men; mean ± SEM age 61 ± 12.74 years, range 46–84 years). Of the 11 patients, 3 had type II (classic) DM, 2 had type III (malignancy-associated) DM, 1 had type V (overlap) DM, and 5 had type VI (amyopathic) DM. Detailed patient data are given in Table 2.

Clinical lesions of patients with DM were evaluated routinely during patient visits. This documentation was the basis for retrospectively determining the skin involvement, using the Cutaneous Dermatomyositis Activity Index (CDASI).[3] Disease activity at the time of first MTX treatment (baseline) was compared with that after 2–3 months (under treatment). Response to treatment was defined as a decline in skin lesions or reduction in CK levels by > 50% within 3 months, as described previously.[4] The observation period was chosen based on earlier prospective findings[5] showing significant efficacy of MTX within this period.

© The Author(s)
CED © 2011 British Association of Dermatologists

资料来自互联网，仅供科研和教学使用，使用者请于24小时内自行删除

Histological analyses of DM skin lesions

The available primary histological (haematoxylin and eosin) slides (n = 9) were blinded and re-evaluated by two of the authors (JW and TH). The extent of the lesional inflammation was scored semiquantitatively (from 0 = weak to 3 = strong) as described previously.[6]

Strategy for methotrexate treatment

To avoid complications, patients were selected carefully before MTX treatment. Importantly, this treatment was not considered when kidney, liver or lung function was impaired. Patients with ulceration of the gastrointestinal tract, alcohol abuse, bone-marrow depression, severe diabetes mellitus or persistent infections were excluded. Pregnancy was an absolute contraindication.

Therapy was generally started at a dose of 5 or 7.5 mg/week subcutaneously, and then increased, depending on the individual patient's course, in steps of 5 mg up to a maximum of 25 mg/week (minimum 7.5 mg/week, average 15 mg/week). In addition, folic acid 5 mg was given routinely 24 h after MTX application to reduce side-effects.

Statistical analyses

To analyse the effectiveness of MTX in DM, we compared the CDASI and the CK serum level at the time points defined above, using the paired nonparametric Wilcoxon test and SPSS software (version 18; SPSS Inc., Chicago, IL, USA). The extent of the lesional inflammation in primary skin biopsies in MTX responders and nonresponders was compared by the Mann–Whitney-*U*-test.

Results

Efficacy of MTX treatment

MTX dosage was 7.5–20 mg/week (mean 14.91 mg/week). In all cases, MTX was used as a second-line treatment in patients, following non-response to systemic corticosteroids. Furthermore, three patients had disease that was recalcitrant to azathioprine, and one patient's disease had not responded to azathioprine and mycophenolic acid.

Most patients treated with MTX had a significant improvement of their skin lesions. The mean CDASI decreased significantly, from 14.1 to 5.5 ($P < 0.01$) (Fig. 1), supporting the effectiveness of MTX in DM skin disease. However, in three patients (pat. no. 2, 9 and 10) MTX had no or only minor effects on the skin symptoms of DM. This finding was independent of the underlying DM type, but MTX was considerably more effective in patients who presented with a cell-rich inflammatory infiltrate in their primary skin biopsy (Fig. 2). MTX treatment was also effective for muscular disease, as shown by the mean CK levels in patients with muscle involvement, which declined significantly, from 776.5 to 143 U/L ($P < 0.01$).

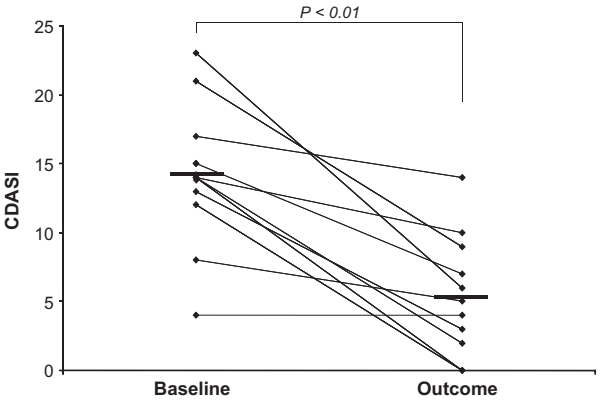

Figure 1 Graphical comparison of Cutaneous Dermatomyositis Activity Index (CDASI) baseline and outcome scores.

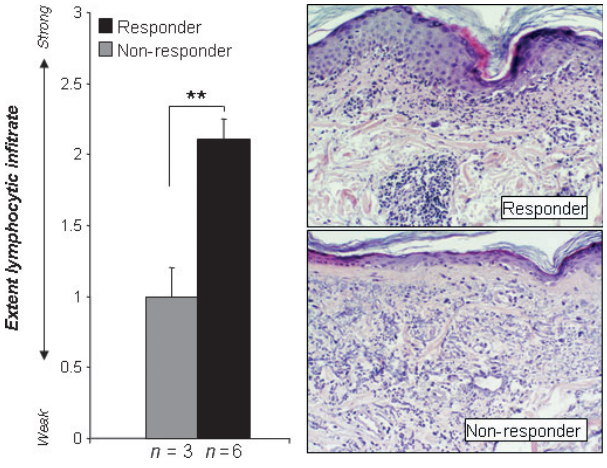

Figure 2 Analysis of the lesional lymphocytic infiltrate in patients with dermatomyositis (DM). All available primary skin biopsies of patients with dermatomyositis who were treated with methotrexate (MTX) (responders, n = 6; nonresponders, n = 3) were analysed for the extent of the inflammatory infiltrate. Figure 1 depicts the mean value in these groups (**$P < 0.01$), and shows two representative skin samples (haematoxylin and eosin, original magnification × 200).

© The Author(s)

资料来自互联网，仅供科研和教学使用，使用者请于24小时内自行删除

Side-effects of MTX treatment

During MTX treatment, two patients developed life-threatening side-effects (herpes encephalitis and pancytopenia), but both recovered after discontinuation of MTX and specific treatment for the condition. Both had to be admitted for inpatient care for an average of 20 days. In one patient, an urothelial carcinoma was diagnosed 14 weeks after MTX initiation, and one patient developed an injection-site abscess. All these patients had received MTX 15 mg/week subcutaneously.

Discussion

In 1968, Malaviya *et al.*[7] were the first to use MTX in the treatment of DM, and they reported an 'improvement of muscular strength to normal or near normal and a disappearance of the rash' in four patients after weekly intravenous administration of MTX 50–100 mg. During the following decades, sporadic case reports and case series supported the effectiveness of MTX in DM. Only one prospective study dealt with MTX in DM (n = 10);[5] however, this and most of the earlier studies focused on muscle disease in DM, rather than skin lesions (Table 1). This was perhaps because there was no specific skin score for DM at the time, as the CDASI was only developed in 2008,[3] even though skin-specific symptoms have a marked effect on patients' quality of life.[8] To our knowledge, no previous work has assessed efficacy of MTX on skin symptoms by using a validated score, or suggested a correlation between clinical response to MTX in DM and histological features. However, this is a retrospective analysis, and it is important to bear in mind that the information is limited and subject to possible confounding and bias.

In this study, the clinical response rate of the DM skin lesions to low-dose MTX was 73%. Subcutaneously administrated low-dose MTX generally led to a good improvement of skin lesions, as shown by a significant decrease in CDASI. Only three patients did not respond. We saw the best clinical results in those patients who presented with a marked lymphocytic inflammatory infiltrate in the skin, whereas the skin lesions of nonresponders were histologically characterized by weak inflammation. This indicates that the inhibition of the lymphocyte migration into the peripheral tissue might be a principal effect of MTX in DM, as proposed previously in other autoimmune skin diseases, including psoriasis[9] and cutaneous lupus erythematosus.[10] However, further prospective studies are needed to confirm these retrospective data.

In conclusion, this study supports earlier evidence for the use of MTX for skin disease in DM, shown by the recently developed CDASI, and identifies cutaneous lymphocytes as potential targets of this treatment.[10] As DM often occurs as a paraneoplastic disease and our data indicate an antilymphocytic, immunosuppressive effect of low-dose MTX in DM, this drug should be used with great care in patients with suspected malignancies.

References

1 Bohan A, Peter JB. Polymyositis and dermatomyositis (first of two parts). *N Engl J Med* 1975; **292**: 344–7.
2 Euwer RL, Sontheimer RD. Amyopathic dermatomyositis (dermatomyositis sine myositis). Presentation of six new cases and review of the literature. *J Am Acad Dermatol* 1991; **24**: 959–66.
3 Klein RQ, Bangert CA, Costner M *et al.* Comparison of the reliability and validity of outcome instruments for cutaneous dermatomyositis. *Br J Dermatol* 2008; **159**: 887–94.
4 Kasteler JS, Callen JP. Low-dose methotrexate administered weekly is an effective corticosteroid-sparing agent for the treatment of the cutaneous manifestations of dermatomyositis. *J Am Acad Dermatol* 1997; **36**: 67–71.
5 Vencovsky J, Jarosova K, Machacek S *et al.* Cyclosporine A versus methotrexate in the treatment of polymyositis and dermatomyositis. *Scand J Rheumatol* 2000; **29**: 95–102.
6 Wenzel J, Worenkamper E, Freutel S *et al.* Enhanced type I interferon signalling promotes Th1-biased inflammation in cutaneous lupus erythematosus. *J Pathol* 2005; **205**: 435–42.
7 Malaviya AN, Many A, Schwartz RS. Treatment of dermatomyositis with methotrexate. *Lancet* 1968; **2**: 485–8.
8 Hundley JL, Carroll CL, Lang W *et al.* Cutaneous symptoms of dermatomyositis significantly impact patients' quality of life. *J Am Acad Dermatol* 2006; **54**: 217–20.
9 Sigmundsdottir H, Johnston A, Gudjonsson JE *et al.* Methotrexate markedly reduces the expression of vascular E-selectin, cutaneous lymphocyte-associated antigen and the numbers of mononuclear leucocytes in psoriatic skin. *Exp Dermatol* 2004; **13**: 426–34.
10 Wenzel J, Brahler S, Bauer R *et al.* Efficacy and safety of methotrexate in recalcitrant cutaneous lupus erythematosus: results of a retrospective study in 43 patients. *Br J Dermatol* 2005; **153**: 157–62.

© The Author(s)
CED © 2011 British Association of Dermatologists

资料来自互联网，仅供科研和教学使用，使用者请于24小时内自行删除

This document is a scanned copy of a printed document. No warranty is given about the accuracy of the copy. Users should refer to the original published version of the material.

资料来自互联网，仅供科研和教学使用，使用者请于24小时内自行删除