

Efficacy and safety of Erbium-doped Yttrium Aluminium Garnet fractional resurfacing laser for treatment of facial acne scars

Balakrishnan Nirmal, Sathish B. Pai, Hanumanthu Sripathi, Raghavendra Rao, Smitha Prabhu, Mohan H. Kudur, Sudhir C. K. Jayak

Department of Dermatology,
Kasturba Medical College,
Manipal University, Manipal,
India

Address for correspondence:

Dr. Sathish B. Pai,
Department of Dermatology,
Kasturba Medical College,
Manipal University,
Manipal, India.
E-mail: drsbpai@yahoo.co.in

ABSTRACT

Background: Treatment of acne scars with ablative fractional laser resurfacing has given good improvement. But, data on Indian skin are limited. A study comparing qualitative, quantitative, and subjective assessments is also lacking. **Aim:** Our aim was to assess the improvement of facial acne scars with Erbium-doped Yttrium Aluminium Garnet (Er:YAG) 2940 nm fractional laser resurfacing and its adverse effects in 25 patients at a tertiary care teaching hospital. **Methods:** All 25 patients received four treatment sessions with Er:YAG fractional laser at 1-month interval. The laser parameters were kept constant for each of the four sittings in all patients. Qualitative and quantitative assessments were done using Goodman and Barron grading. Subjective assessment in percentage of improvement was also documented 1 month after each session. Photographs were taken before each treatment session and 1 month after the final session. Two unbiased dermatologists performed independent clinical assessments by comparing the photographs. The kappa statistics was used to monitor the agreement between the dermatologists and patients. **Results:** Most patients (96%) showed at least fair improvement. Rolling and superficial box scars showed higher significant improvement when compared to ice pick and deep box scars. Patient's satisfaction of improvement was higher when compared to physician's observations. No serious adverse effects were noted with exacerbation of acne lesions forming the majority. **Conclusion:** Ablative fractional photothermolysis is both effective and safe treatment for atrophic acne scars in Indian skin. Precise evaluation of acne scar treatment can be done by taking consistent digital photographs.

Key words: Acne scars, fractional laser, photographs

INTRODUCTION

Atrophic scars are the dermal depressions commonly caused by the destruction of collagen after inflammatory acne.^[1] Many therapeutic measures such as chemical peeling,^[2] subcision,^[3] dermabrasion,^[4] fillers,^[5] and punch techniques^[6] have been performed to improve

acne scarring but with suboptimal outcomes. Although significant clinical improvements can be seen with ablative lasers, adverse effects such as prolonged post-procedure erythema^[7] and dyspigmentation^[8] impede their widespread use especially in patients with darker skin. On the other hand, non-ablative lasers^[9] such as diode, Neodymium-doped Yttrium Aluminum Garnet (Nd:YAG) and pulsed dye laser have better safety profiles but lower efficacies. Fractional laser resurfacing technique^[10] was developed to address the drawbacks of both ablative and non-ablative lasers.

However, data on the efficacy and adverse effects of this novel resurfacing technique in Indian skin are limited. Also a good clinical study comparing

Access this article online	
Quick Response Code	Website: www.ijdv.com
	DOI: 10.4103/0378-6323.107635

How to cite this article: Nirmal B, Pai SB, Sripathi H, Rao R, Prabhu S, Kudur MH, *et al.* Efficacy and safety of Erbium-doped Yttrium Aluminium Garnet fractional resurfacing laser for treatment of facial acne scars. Indian J Dermatol Venereol Leprol 2013;79:193-8.

Received: June, 2012. **Accepted:** October, 2012. **Source of Support:** Nil. **Conflict of Interest:** None declared.

qualitative and quantitative assessments of pre- and post-treatment photographs after standardizing them, along with subjective assessment is lacking.

METHODS

Aim and objectives

Our aim and objectives were to assess the improvement of acne scars quantitatively, qualitatively and subjectively; then to estimate the improvement with respect to duration, grade and type of acne scars. We also wanted to look for the most common adverse reactions and their incidence.

Study design

The study was designed as a clinical trial using fractional laser resurfacing for the treatment of atrophic facial acne scars in 25 patients from June 2010 to October 2011. Patients diagnosed with atrophic acne scarring aged 18 years or above were included. Those with known photosensitivity, pregnancy, lactation, keloidal tendency, use of oral retinoids in last 6 months, infections like herpes labialis, active acne illness in last 4 weeks, and unrealistic expectations were excluded.

Ethical considerations

A written and signed informed explanatory consent was taken from all the patients before initiation of therapy. This clinical study was performed in accordance with the declaration of Helsinki after approval by the ethic committee of our hospital.

Laser treatment

All 25 patients received four sessions of laser treatment at 1-month interval. They were treated with fractional ablative resurfacing mode using 2940 nm Er:YAG handpiece. A cooling device delivering cold air was used to reduce pain sensation during and after treatment. Parameters for each sitting were kept constant in all patients. First and second sessions were performed using 9×9 tips with fluence of 1,200 and 1,400 mJ, respectively. Third and fourth sessions were performed using 7×7 tips with fluence of 1,200 and 1,400 mJ respectively. Long pulse mode (2 Hz) was used for all four sessions. Three passes in vertical, horizontal, and oblique directions with upto 50% overlapping between the adjacent pulses and stacking was done over scar areas where five pulses were given in exactly same place without moving the tip. Strict photoprotection was advised as a routine and topical antibiotic-steroid combination was applied for 3 days post-procedure.

Assessment of efficacy

Qualitative assessment

Qualitative assessment was done using Goodman and Barron (GB) qualitative global scarring grading system^[11] which has four grades viz., macular, mild, moderate and severe.

Quantitative assessment

Quantitative assessment was done using GB quantitative global scarring grading system.^[12] Different types of scars were given increasing scores and multiplied depending on the number of scars in each type giving a maximum score of 84.

Subjective assessment

The patients were asked to quantify their percentage of improvement 1 month after each treatment session and their subjective assessment of improvement of scar was also documented.

Photography assessment

We designed an instrument [Figure 1] in our workshop to ensure that photographs were taken with identical patient positioning, lighting, and camera settings. Small inconsistencies with patient positioning were corrected using image analysis software.

Serial photographs were assessed by two unbiased, certified dermatologists. Physician evaluations and patient satisfaction were graded on a four-point scale viz., none, fair, good, and excellent improvement.

Assessment of safety

Subjects were instructed to report any cutaneous side-effects including erythema, oozing, crusting, dyschromia, scarring or secondary infection after laser treatment. Patients were specifically asked about immediate post-treatment sequelae and about interference with daily activities in the post-treatment period and report if any.

Statistical analysis

The results were statistically analyzed using SPSS version 11.0 (SPSS, Inc., Chicago, IL, USA). Differences were considered statistically significant when $p < 0.05$. The kappa statistic was used as a measure of agreement between physicians and patients.

RESULTS

Patient demographics

A total of 25 patients with acne scars of skin phototypes IV-V participated in the study comprising of 15 males

(60%) and 10 females (40%). They belonged to the age group of 18-38 years. The duration of scars ranged from as less as 6 months to 15 years. Most patients had grade 4 acne scars constituting 48% (12 cases) of the



Figure 1: The instrument used for taking consistent photographs

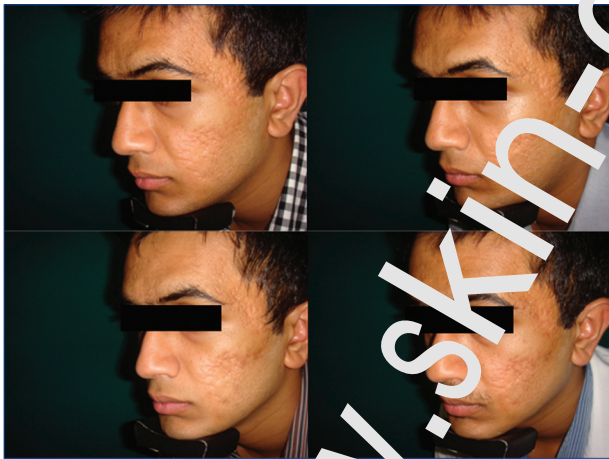

Figure 2: Digital photographs after first, second, third, and fourth sittings

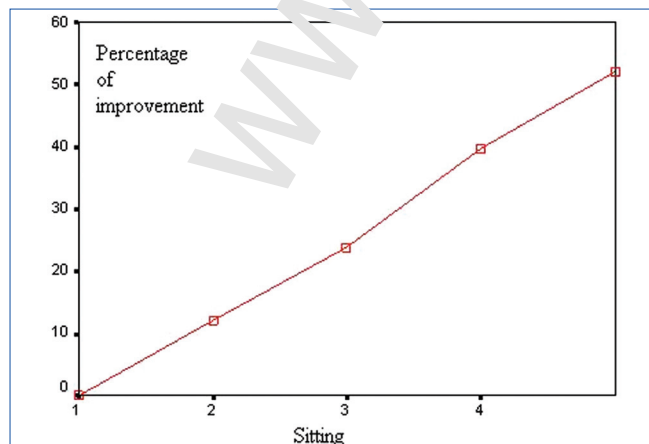


Figure 3: Graph showing the percentage of improvement after each sitting

study population followed by grade 2 (seven cases), grade 3 (six cases), and nil in grade 1. Superficial box, deep box, rolling, ice pick scars were present predominately in eight, seven, seven, and three cases, respectively.

Estimation of improvement with respect to the type of scar

Analysis of covariance was performed and results were evaluated using GB quantitative score-before treatment value of 27.60 as covariate. The difference in mean values between rolling (16.7) and ice pick scars (20.54) after adjusting for the GB-before scores at 27.6 was statistically significant ($p = 0.028$). The superficial box (16.18) also showed a statistically significant ($p = 0.030$) difference in the mean as compared to the ice pick scars [Table 1]. There was no statistically significant difference in the mean values between deep box (17.86) and ice pick scars ($p = 0.095$).

There was no statistically significant variation of improvement with respect to duration as well as grade of acne scars.

Comparison of patient satisfaction between sittings

The patient's satisfaction between first, second, third, and fourth sittings [Figure 2] was computed using general linear model. Higher significant improvement was seen after the third sitting with the mean improvement in the GB quantitative score increasing to 15.8 after third sitting [Table 2]. The graph [Figure 3] shows the steep increase in improvement after the third sitting.

Table 1: Goodman Barron - after treatment scores: using Goodman Barron - before treatment value of 27.60 as covariate

Scartype	GB score after treatment	P value
Rolling	16.70	0.028
Superficial box	16.18	0.030
Deep box	17.86	0.095
Ice pick	20.54	-

GB: Goodman Barron grading score

Table 2: Mean improvement in the Goodman Barron quantitative scores after each sitting

Treatment sessions	Improvement mean	Improvement cumulative mean
1 st sitting	12.2	12.2
2 nd sitting	11.6	23.8
3 rd sitting	15.8	39.6
4 th sitting	12.4	52.0

Comparison of patient’s satisfaction and inter-observer variation

Patient’s satisfaction scores were higher in comparison to both observers’ rating with a relatively higher proportion of improvement grading in the good and excellent categories [Table 3]. The kappa statistic was used to monitor the agreement between observers, patient and observer-1, and patient and observer-2. The observers [Figure 4] showed statistically significant [Table 4] substantial agreement between each other ($\kappa=0.61-0.8$), whereas the patient’s agreement with observer-1 and observer-2 was only slight ($\kappa=0-0.2$).

Adverse reactions

Most common side-effect seen after 100 sittings (25 patients \times 4 sittings each) of Er:YAG 2940nm fractional laser resurfacing was exacerbation of acne lesions (13%) which was treated with oral antibiotics. Post-treatment pigmentation was seen only in 2% and was effectively treated with demelanizing creams. Prolonged crusting (more than 7 days) was seen after 3% of the sittings. None of the patients had prolonged erythema (more than 4 days) after undergoing treatment sessions. The mean erythema duration was less than 2 days and mean crusting was around 5 days in all sittings [Table 5]. Figure 5 shows the appearance immediately after the laser treatment showing the stamping effect of pixel laser, 1 day post-treatment showing erythema, 3 days post-treatment showing crusting, and 7 days post-treatment with complete clearance of erythema and crusting.

DISCUSSION

Resurfacing lasers date back to 1980s using ablative carbondioxide lasers,^[13] which are based on the theory

of selective photothermolysis.^[14] Non-ablative lasers were developed to combat the side-effect profiles of ablative lasers but had unpredictable efficacy. Fractional photothermolysis (FP) was devised by Manstein and colleagues in 2004.^[15] The results of first fractional non-ablative laser (1,550 nm Er:glass laser)^[16] were still unsatisfactory. The need for better results led to the combination of the theory of FP and ablative laser technologies producing ablative fractional resurfacing^[17] to address the drawbacks of both ablative and non-ablative lasers, thus

Table 3: Grading of improvement by patient and observers

Improvement (%)	Patient	Observer-1	Observer-2
None (0-5)	1	1	2
Fair (26-50)	14	19	17
Good (51-75)	7	5	6
Excellent (76-100)	3	0	0

Table 4: Kappa statistic analysis

Comparison	κ value	P value
Observer-1 vs. observer-2	0.628	0.006
Observer-1 vs. patient	0.123	0.538
Observer-2 vs. patient	0.038	0.835

Table 5: Mean erythema and crusting after each sitting

Treatment sessions	Mean erythema duration (in days)	Mean crusting duration (in days)
1 st sitting	1.28	4.68
2 nd sitting	1.40	4.68
3 rd sitting	1.60	5.16
4 th sitting	1.50	4.84

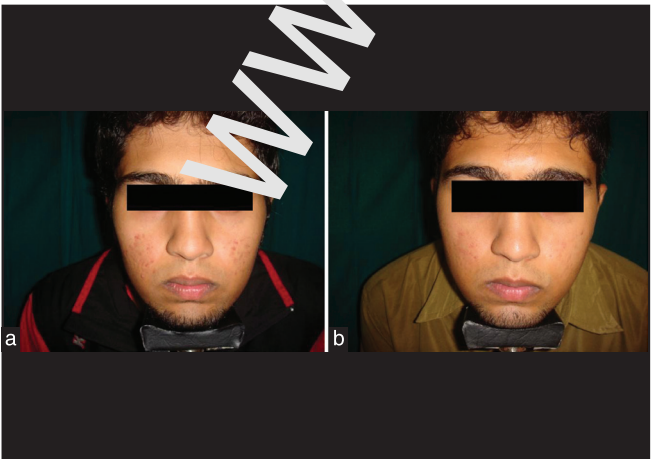


Figure 4: Patient, observer-1, and observer-2 agreed good (50-75%) improvement (a) before treatment (b) after treatment

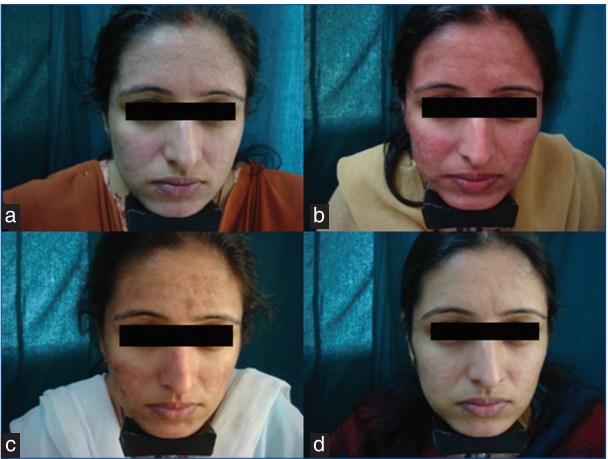


Figure 5: Sequence of events post- laser treatment: (a) Immediate post laser, (b) 1 day post laser, (c) 3 days post laser, (d) 7 days post laser

considered “the best of both worlds.” The principle of FP is targeting water as a chromophore. Water-rich targets in skin include epidermal keratinocytes, collagen and blood vessels.^[18] FP involves the application of multiple beams of pixilated light producing microscopic treatment zones.^[19] Thermal damage initiates a biological signaling cascade^[20] leading to increased expression of heat shock protein which causes upregulation of transforming growth factor beta, a facilitator of collagen synthesis.^[21] Healing is faster since most of the surrounding tissue is spared from thermal damage with replacement of epidermis and expulsion of microscopic exudative necrotic debris, composed of elastin and melanin.^[22]

This study demonstrates that Er:YAG 2940 nm fractional resurfacing laser effectively improves acne scars with minimal downtime and a low risk of adverse reactions. After four treatments with Er:YAG 2940 nm fractional laser, 24 out of 25 subjects rated themselves as having at least 25-50% overall satisfaction which was similar to the physicians' grading. This observation was consistent with the finding of fractional laser in darker skin types by Manuskiatti *et al.*,^[23] Hu *et al.*,^[24] Alster *et al.*,^[25] and Mahmoud *et al.*^[26] The difference in agreement was noticed when observing the number of patients reporting more than 50% improvement (good to excellent) as compared with the observers' rating. Forty percent of the subjects noticed good to excellent improvement as opposed to 9-24% in the observers. Patients felt better probably because of the additional benefits of fractional laser in decreasing pigmentation, decreasing fine lines, skin tightening, and pore reduction. This is the reason why though the patients had only a fair improvement after pixel laser, they felt the laser's efficacy to be good or

excellent. Twelve percent of the patients reported excellent improvement with the highest being 85% improvement.

Post-inflammatory hyperpigmentation (PIH) was the most common side effect as observed by Manuskiatti *et al.*^[23] in 92.7% patients. In our experience, PIH [Figure 6] was low (2%) in Er:YAG ablative fractional resurfacing, suggesting that it can be safely performed in Indian skin. Our findings were consistent with that observed by Hu *et al.*,^[27] where also the incidence of PIH was less, seen only in 3% of the cases in 34 patients with Fitzpatrick skin types III and IV using ablative fractional Er:YAG laser. Downtime was also acceptable in our study with mean value less than 7 days in all four sittings. Prolonged erythema was seen in one of the sittings and only 3% showed prolonged crusting. Exacerbation of acne lesions [Figure 7] was the most common adverse effect of fractional laser in our study which developed after 13% of the sittings which could be due to the steroid-antibiotic cream used for 3 days after treatment. This was comparable to the observations by Hu *et al.*^[27] in his study of 34 patients using Er:YAG laser for atrophic facial acne scars in Asian skin where acne eruption was seen in 24.2% of patients.

CONCLUSION

Ninety-six percent of the subjects rated themselves as having at least fair improvement. Rolling and superficial box scars showed higher significant improvement when compared to ice pick and deep box scars. Patient's satisfaction of improvement was higher when compared to physician's observations and it increased markedly after third sitting. Incidence

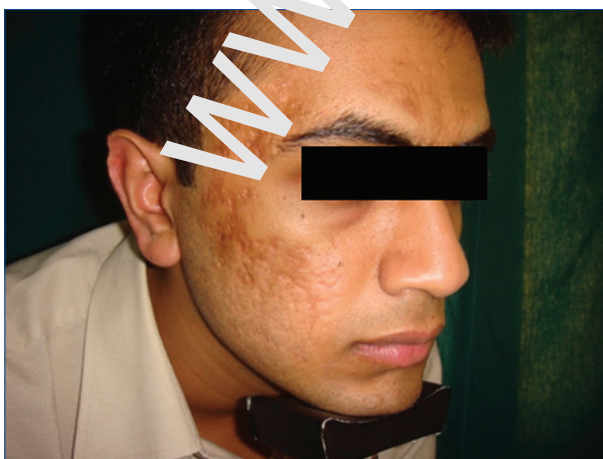

Figure 6: Post-inflammatory hyper pigmentation

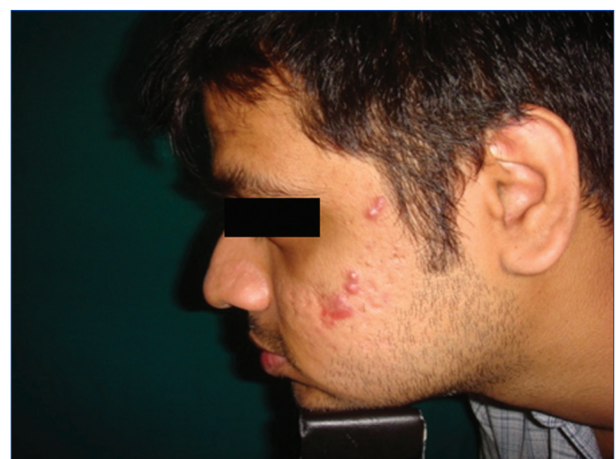

Figure 7: Exacerbation of acne lesions

of adverse effects post-laser was very less and period of recovery was also not prolonged. Thus, the results of this study support the use of FP for the safe and effective treatment of atrophic facial acne scars.

FUTURE RECOMMENDATIONS

As improvement in patient rating increases markedly after third sitting and incidence of side-effects was minimal even in type V skin, we recommend future studies to start with the fluence of third sitting over scar area and regular protocol on rest of the face similar to spot peels for melasma where higher concentration is used over pigmented area and lower concentration over the rest of the face. As the improvement was increasing with every sitting, we also recommend further studies to be undertaken with more treatment sessions.

ACKNOWLEDGMENTS

We would like to acknowledge our professors Dr. Shrutakathi D. Sheno and Dr. C. Balachandran for their observation and assessment of photographs in this study. We also thank Dr. Asha Kamath, Assistant professor, Department of Community Medicine, Kasturba Medical College, Manipal for statistical analysis of the data. We would like to thank the patients for providing consent to use their photographs in this article.

REFERENCES

- Holland DB, Jeremy AH, Roberts SG, Seukeran DC, Layton AM, Cunliffe WJ. Inflammation in acne scarring: A comparison of the responses in lesions from patients prone and not prone to scar. *Br J Dermatol* 2004;150:72-81.
- Slavin JW. Trichloroacetic acid peels. *Aesthet Surg J* 2004;24:469-70.
- Orentreich DS, Orentreich N. Cutaneous incisionless (subcision) surgery for the correction of depressed scars and wrinkles. *Dermatol Surg* 2005;21:543-9.
- Alkhawam L, Alam M. Dermabrasion and microdermabrasion. *Facial Plast Surg* 2009;25:311-9.
- Hirsch RJ, Cohen JL. Soft tissue augmentation. *Cutis* 2006;78:165-72.
- Grevelink JM, White WR. Concurrent use of laser skin resurfacing and punch excision in the treatment of facial acne scarring. *Dermatol Surg* 1998;24:327-30.
- Dierickx CC, Khatri KA, Tannous ZS, Childs JJ, Cohen RH, Erofeev A, et al. Micro-fractional ablative skin resurfacing with two novel erbium laser systems. *Lasers Surg Med* 2008;40:113-23.
- Kono T, Chan HH, Groff WF, Manstein D, Sakurai H, Takeuchi M, et al. Prospective direct comparison study of fractional resurfacing using different fluences and densities for skin rejuvenation in Asians. *Lasers Surg Med* 2007;39:311-4.
- Alexiades-Armenakas MR, Dover JS, Arndt KA. The spectrum of laser skin resurfacing: Nonablative, fractional, and ablative laser resurfacing. *J Am Acad Dermatol* 2008;58:719-37.
- Tierney EP, Kouba DJ, Hanke CW. Review of fractional photothermolysis: Treatment indications and efficacy. *Dermatol Surg* 2009;35:1445-61.
- Goodman GJ, Baron JA. Postacne scarring: A qualitative global scarring grading system. *Dermatol Surg* 2006;32:1458-66.
- Goodman GJ, Baron JA. Postacne scarring: A quantitative global scarring grading system. *J Cosmet Dermatol* 2006;5:48-52.
- Brightman L, Brauer JA, Anolik R, Weiss E, Karen J, Chapas A, et al. Ablative and fractional ablative lasers. *Dermatol Clin* 2009;27:473-80.
- Anderson RP, Parrish JA. Selective photothermolysis: Precise microsurgery by selective absorption of pulsed radiation. *Science* 1983;220:524-7.
- Manstein D, Herron GS, Sink RK, Tanner H, Anderson RR. Fractional photothermolysis: A new concept for cutaneous remodeling using microscopic patterns of thermal injury. *Lasers Surg Med* 2004;34:426-38.
- Bouendord MO, Grunewald S, Wetzig T, Simon JC, Paasch U. Fractional laser skin therapy. *J Dtsch Dermatol Ges* 2009;7:301-8.
- Goel A, Krupashankar DS, Aurangabadkar S, Nischal KC, Omprakash HM, Mysore V. Fractional lasers in dermatology—Current status and recommendations. *Indian J Dermatol Venereol Leprol* 2011;77:369-79.
- Hantash BM, Bedi VP, Kapadia B, Rahman Z, Jiang K, Tanner H, et al. *In vivo* histological evaluation of a novel ablative fractional resurfacing device. *Lasers Surg Med* 2007;39:96-107.
- Khan MH, Sink RK, Manstein D, Eimerl D, Anderson RR. Intradermally focused infrared laser pulses: Thermal effects at defined tissue depths. *Lasers Surg Med* 2005;36:270-80.
- Tierney EP, Kouba DJ, Hanke CW. Review of fractional photothermolysis: Treatment indications and efficacy. *Dermatol Surg* 2009;35:1445-61.
- Hantash BM, Mahmood MB. Fractional photothermolysis: A novel aesthetic laser surgery modality. *Dermatol Surg* 2007;33:525-34.
- Laubach HJ, Tannous Z, Anderson RR, Manstein D. Skin responses to fractional photothermolysis. *Lasers Surg Med* 2006;38:142-9.
- Manuskiatti W, Triwongwanarat D, Varothai S, Eimpunth S, Wanitphakdeedecha R. Efficacy and safety of a carbon-dioxide ablative fractional resurfacing device for treatment of atrophic acne scars in Asians. *J Am Acad Dermatol* 2010;63:274-83.
- Hu S, Chen MC, Lee MC, Yang LC, Keoprasom N. Fractional resurfacing for the treatment of atrophic facial acne scars in Asian skin. *Dermatol Surg* 2009;35:826-32.
- Alster TS, Tanzi EL, Lazarus M. The use of fractional laser photothermolysis for the treatment of atrophic scars. *Dermatol Surg* 2007;33:295-9.
- Mahmoud BH, Srivastava D, Janiga JJ, Yang JJ, Lim HW, Ozog DM. Safety and efficacy of erbium-doped yttrium aluminum garnet fractionated laser for treatment of acne scars in type IV to VI skin. *Dermatol Surg* 2010;36:602-9.
- Hu S, Hsiao WC, Chen MC, Huang YL, Chang SL, Shih PY, et al. Ablative fractional erbium-doped yttrium aluminum garnet laser with coagulation mode for the treatment of atrophic acne scars in Asian skin. *Dermatol Surg* 2011;37:939-44.

Copyright of Indian Journal of Dermatology, Venereology & Leprology is the property of Medknow Publications & Media Pvt. Ltd. and its content may not be copied or emailed to multiple sites or posted to a listserv without the copyright holder's express written permission. However, users may print, download, or email articles for individual use.

www.skin-disease.cn