doi: 10.1111/j.1346-8138.2008.00555.x

CASE REPORT

Postmenopausal frontal fibrosing alopecia in a Japanese woman with Sjögren's syndrome

Makito SATO[1,3], Kenji SAGA[2] and Hiroyuki TAKAHASHI[3]

[1]*Department of Dermatology, Sapporo Medical University,* [2]*Kojinkai Sapporo Dermatology Clinic, and* [3]*Sapporo Kosei General Hospital, Sapporo, Japan*

ABSTRACT

Postmenopausal frontal fibrosing alopecia (PFFA) is a rare alopecia that develops in the frontoparietal scalp of postmenopausal women. Etiology of PFFA is unknown. Most of cases of PFFA have been reported in European and North American countries. Herein, we report a Japanese case of PFFA associated with Sjögren's syndrome. A 66-year-old woman had had slowly progressive, band-like, scarring alopecia on her frontoparietal scalp. Hair follicles on the margin showed follicular keratosis. Histologically, fibrosis and lymphocytic infiltration were mild. This case suggests that PFFA may show mild inflammatory reaction and mild fibrosis in Japanese women. The association with immunological disorders including Sjögren's syndrome should be studied further.

Key words: frontoparietal scalp, hairline regression, Sjögren's syndrome.

INTRODUCTION

Kossard first described postmenopausal frontal fibrosing alopecia (PFFA) in 1994.[1] This condition presents a unique clinical manifestation that is characterized by a symmetrical and progressive recession of the frontoparietal hairline mostly in postmenopausal women. Histological findings show a reduction or loss of terminal hair follicles and a replacement by fibrosis around affected hair follicles. In addition, lymphocytic infiltration is usually observed in a lichenoid pattern in the upper dermis. PFFA is now considered as a variant of lichen planopilaris.[2] Although the pathogenesis of this disorder still remains to be clarified, a unique clinical picture and predominant onset in postmenopausal women suggest that the hormonal factors are responsible for some, but not all, patients.[3] We will report a Japanese case of PFFA that was associated with Sjögren's syndrome (SjS).

CASE REPORT

A 66-year-old Japanese woman who had a hair loss lesion in a band-like fashion on the frontoparietal portion of her scalp visited us in July 1999. Her hair loss had started in 1993, approximately 5 years after menopause, and the lesion had gradually progressed. There was a band-like alopecia on the frontoparietal scalp (Fig. 1). The alopecia extended to the temporal scalp (Fig. 2). A few islands of hairs were remaining in the lesion of band-like alopecia. A punctate keratinization on the hair follicles and fine scales around hair shafts were observed on the margin. No remarkable atrophic change was seen on the lesional skin. Subjective complaints including itch went unnoticed and her eyebrows and hair of other parts of the body, as well as fingernails and toenails, were not affected. There was no loss of hairs on the occipital scalp. Hairs on the parietal scalp were not sparse. Neither ocular nor oral mucosa was affected.

Correspondence: Kenji Saga, M.D., Ph.D., Kojinkai Sapporo Dermatology Clinic, H&B Plaza 5th Floor, Minami 3 Nishi 2, Chyuo-ku, Sapporo 060-0063, Japan. Email: xh6k-sg@asahi-net.or.jp
Received 21 September 2006; accepted 16 June 2008

© 2008 Japanese Dermatological Association

Figure 1. Symmetrical alopecia is present on the frontoparietal scalp in a band-like fashion.

Figure 2. Alopecia extends to the parietal scalp. Islands of thin hairs are remaining in the lesion of band-like alopecia.

The skin biopsy from the frontal scalp demonstrated a slight hyperkeratosis and thinning of the epidermis. Hair follicles were absent, and the dermis showed minor fibrosis (Fig. 3). A small number of mononuclear cells infiltrated around the blood vessels in the dermis. We therefore diagnosed this case as PFFA. Laboratory examinations showed positive reactions for rheumatoid factor (36 IU/mL), antinuclear antibody (160×), and anti-Ro/SS-A. Secretion of tear and saliva was decreased. A biopsy of oral mucosa and sialography confirmed the diagnosis of SjS. A couple of treatments for alopecia, such as topical carpronium solution, topical corticosteroid as well as short-term administration of systemic corticosteroid, failed to arrest the progression of alopecia in our patient.

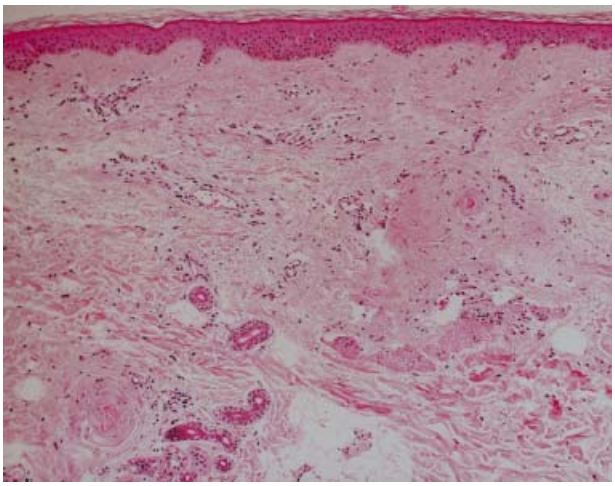

Figure 3. Skin biopsy shows a slightly atrophic epidermis and a small number of inflammatory cells in a fibrotic dermis. There are no hair structures and sweat glands are not involved (HE, original magnification ×170).

DISCUSSION

The present case showed progressive regression of the frontal hairline in a postmenopausal Japanese woman. The regression of the hairline was symmetrical and it was accentuated on both sides of the frontal scalp. Keratotic plugging was observed in the hair follicles on the margin of the alopecia. Scarring on the alopecia was clinically minimal. Histopathology demonstrated minimal fibrosis. The inflammatory cells in this case were small in number and not distributed in a lichenoid fashion. These findings could be attributed to the disease being at different stages when the biopsy was taken. We took a biopsy from a long-lasting lesion. Androgenetic alopecia was excluded because this condition does not affect the frontal scalp in women.[4] Alopecia areata was excluded because alopecia areata is neither symmetrical, nor scarring. Ophiasis-type alopecia areata was unlikely because the occipital scalp was not involved. Taken together, we diagnosed this case as PFFA.

Most cases of PFFA have been reported in European and North American countries while only a few patients have been described in Asian countries, including Japan.[5] The small number of reports of PFFA from Japan suggests that the incidence of

© 2008 Japanese Dermatological Association

PFFA may be lower in Japan than in European and North American countries. Clinical pictures and histological findings of the present case were mild in fibrosis and lymphocytic infiltration. These results suggest that a racial difference may exist in the clinical presentation of PFFA. Namely, PFFA may show mild inflammatory reaction and mild fibrosis in Japanese women.

Postmenopausal frontal fibrosing alopecia rarely occurs in a patient of SjS. The association of connective tissue diseases with PFFA has not been reported except for the presence of antinuclear antibodies in some cases.[6] An immunological alterations as well as hormonal interaction may play important roles in the course of PFFA. The lichenoid tissue reaction finally results in a selective destruction of the androgen-dependent frontal hair follicles as recently reported by Tosti *et al*.[6] Further studies are needed to clarify the relationship between PFFA and SjS.

Because topical and systemic steroids failed to control the disease progression in our patient, successful treatments with finasteride and others[7] have yet to be established. Kossard *et al.* reported that none of the following therapies altered the course of PFFA, including oral prednisone, topical corticosteroids, chloroquine phosphate, isotretinoin and hormone replacement therapy.[2]

ACKNOWLEDGEMENTS

The authors thank Dr Y. Gotoda and Dr S. Muraoka, Department of Pathology, Sapporo-Kosei General Hospital, for critical advice, and Mr H Ito, Medical Photographic Center, Sapporo Medical University, for photographic works.

REFERENCES

1 Kossard S. Postmenopausal Frontal Fibrosing alopecia: scarring alopecia in a pattern distribution. *Arch Dermatol* 1994; **130**: 770–774.
2 Kossard S, Lee MS, Wilkinson B. Postmenopausal frontal fibrosing alopecia: a frontal variant of lichen planopilaris. *J Am Acad Dermatol* 1997; **36**: 59–66.
3 Zinkernagel MS, Trueb RM. Fibrosing alopecia in a pattern distribution: patterned lichen planopilaris or androgenetic alopecia with a lichenoid tissue reaction pattern? *Arch Dermatol* 2000; **136**: 205–211.
4 Bienova M, Kucerova R, Fiuraskova M, Hajduch M, Kolar Z. Androgenetic alopecia and current methods of treatment. *Acta Dermatoven APA* 2005; **14**: 5–8.
5 Murao K. A case of postmenopausal frontal fibrosing alopecia. *Rinsho Derma (Tokyo) (in Japanese)* 2000; **42**: 1061–1063.
6 Tosti A, Piraccini BM, Iorizzo M, Misciali C. Frontal fibrosing alopecia in postmenopausal women. *J Am Acad Dermatol* 2005; **52**: 55–60.
7 Price VH, Roberts JL, Hordinsky M *et al*. Lack of efficacy of finasteride in postmenopausal women with androgenetic alopecia. *J Am Acad Dermatol* 2000; **43**: 768–776.

© 2008 Japanese Dermatological Association

Copyright of Journal of Dermatology is the property of Blackwell Publishing Limited and its content may not be copied or emailed to multiple sites or posted to a listserv without the copyright holder's express written permission. However, users may print, download, or email articles for individual use.