

Report

Pigmentary changes of tinea versicolor in dark-skinned patients

Salih H. M. Aljabre, MBBS, MSc, PhD, Ahmad A. A. Alzayir, MBBS, Magdy Abdulghani, MBBS, and Osman O. Osman, MBBS, DVD

From the Department of Dermatology, King Fahd Hospital of the University, King Faisal University, Alkhobar, Saudi Arabia

Correspondence

Salih H. M. Aljabre, MBBS, MSc, PhD
PO Box 10011
Dammam 31223
Saudi Arabia
E-mail: saljabre@hospital.kfu.edu.sa;
saljabre@yahoo.com

Abstract

Background Tinea versicolor causes scaly macular lesions which vary in color from white to brown. In patients with dark skin, tinea versicolor is thought to have a tendency to be hypopigmented. This view has not been formally documented.

Objective Our objective was to determine the pigmentary changes of lesions of tinea versicolor in patients with skin types IV and V.

Methods One hundred cases of tinea versicolor in persons with skin types IV and V were studied. The pigmentary changes and their correlation with the age and sex of the patients and the duration, recurrence, site, and symptomatology of the lesions were determined.

Results There was no correlation between the pigmentary variations of tinea versicolor and the type of skin, sex, and age of our patients or the duration, recurrence, site, and symptomatology of the lesions.

Conclusions In dark-skinned individuals, tinea versicolor does not tend to be significantly hypopigmented.

Introduction

Tinea versicolor is a superficial infection of the skin by the yeast *Malassezia furfur* which is part of the normal flora of the skin. Scaly macular lesions characterize tinea versicolor. The color of these lesions varies from white to brown. The pathogenesis of these pigmentary variations has not been clearly established. Hypopigmentation has been explained by damage to melanocytes and inhibition of tyrosinase by decarboxylic acid produced by *Malassezia furfur*,¹ by melanosomes of small size,^{2,3} and by blocking of the ultraviolet light by lipid-like material accumulating in the stratum corneum.⁴ Hyperpigmentation has been explained by abnormally large melanosomes,^{5,6} a thick stratum corneum,⁷ and a hyperemic inflammatory response.⁸ In general, tinea versicolor is thought to cause hypopigmented lesions in individuals with dark skin and hyperpigmented lesions in those with white skin. This view has not been formally studied. We report our findings on the pigmentary changes of tinea versicolor lesions in dark-skinned patients.

Patients and methods

One hundred cases of tinea versicolor seen at King Fahd Hospital of the University, Alkhobar, Saudi Arabia, were studied. All patients had skin phototypes IV or V.⁹ A clinical diagnosis of tinea versicolor was confirmed by the golden yellow fluorescence of lesions with Wood's light and the presence of hyphae and clusters of yeasts in direct potassium hydroxide microscopic mounts. The age and sex of the patients, and the pigmentary changes, itching, duration, recurrence, and site of the lesions were studied. Itching was assessed subjectively as mild, moderate, or severe. Mantel-Haenzel corrected chi-squared test, Fisher's exact test, and Mann-Whitney rank sum test were used where appropriate for the statistical analysis.

Results

The age of the patients ranged from 9 to 62 years, with a mean of 29 ± 11.4 years. There were 19 females and 81 males. Hypo- and hyperpigmented lesions were commonly encountered: 55% and 33%, respectively. In nine patients,

273

Table 1 Pigmentation of lesions and other clinical findings

Pigmentation	No. of cases	Age	Duration (years)	Male/Female	Pru.	Rec.
O	55	9–62 (29.7 ± 13.1)	0.02–20 (2.8 ± 3.6)	46/9	6	12
R	33	17–46 (28 ± 8.3)	0.02–10 (2.3 ± 2.6)	25/8	8	6
B	9	17–46 (29.8 ± 11)	0.6–10 (2.5 ± 3.1)	8/1	2	1
E	3	16–38 (27.3 ± 11)	0.02–1 (0.4 ± 0.6)	2/1	2	0

O, hypopigmented; R, hyperpigmented; B, both hypo- and hyperpigmented; E, erythematous; Pru., pruritus; Rec., recurrences.

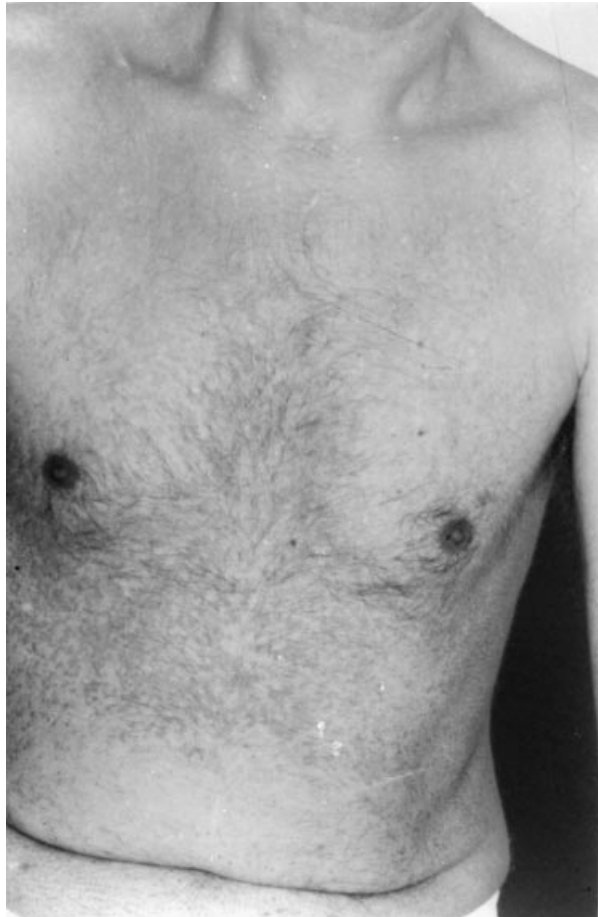


Figure 1 Combination of hypopigmented lesions on the chest and hyperpigmented lesions on the abdomen

there were combinations of hypo- and hyperpigmented lesions either at the same site, trunk in two patients (Fig. 1) and lower limb in one patient, or different sites. Erythematous lesions were present in three cases. Eighteen patients had pruritus which was assessed as mild by all patients. The age and sex of the patients are shown together with the pigmentation, duration, pruritus, and recurrence of the lesions in Table 1. Statistically significant

Table 2 Site of lesions

Pigmentation	No. of cases	Face	Neck	Trunk	UL	LL
O	55	13	29	41	21	4
R	33	3	11	31	12	3
E	3	0	0	3	1	0
B	9	0	3	8	7	2
	1	—	O	B	—	—
	2	—	—	R	O	—
	3	—	—	O	R	—
	4	—	O	—	—	B
	5	—	—	B	O	O
	6	—	—	O	R	—
	7	—	—	R	O	—
	8	—	R	R	O	—
	9	—	—	R	O	—

UL, upper limb; LL, lower limb; 1–9, patients with a combination of hypo- and hyperpigmented lesions; O, hypopigmented; R, hyperpigmented; B, both hypo- and hyperpigmented; E, erythematous.

differences between patients with different pigmentary changes were not found. The site and pigmentation of the lesions are shown in Table 2, but no statistically significant values were found.

Discussion

Alterations of skin pigmentation are presenting complaints in tinea versicolor. The results of our study did not support the tendency for tinea versicolor to be hypopigmented in dark-skinned patients. The coexistence of hypo- and hyperpigmented lesions suggests the involvement of factor(s) other than the normal pigmentation of the skin in the production of the pigmentary changes of lesions of tinea versicolor. The site of the lesions was not influential. In addition, there was no correlation between the changes in pigmentation and the sex or age range of our group of patients. In infants, in tropical areas, severe hypopigmented lesions of tinea versicolor occur in diaper areas. These lesions are called achromia parasitica or tinea versicolor alba.¹⁰

It has been suggested that, initially, lesions are often red or light brown and then the majority become hypopigmented.^{11,12} Others have suggested that, in chronic cases, recent lesions are hypopigmented and older lesions are hyperpigmented.¹⁰ Our study did not confirm either of these views. In addition, pruritus and relapses of lesions were not associated with any particular pigmentary changes. Recently, four new species have been described in the genus *Malassezia*,¹³ and it remains to be determined whether the pigmentary changes of the skin in tinea versicolor are related to different strains. In conclusion, our findings show that, in dark-skinned persons, tinea versicolor does not tend to be hypopigmented.

References

- 1 Nazzaro-Porro M, Passi S. Identification of tyrosinase inhibitor in culture of *Pityrosporum*. *J Invest Dermatol* 1978; 71: 389-402.
- 2 Charles CR, Sire DJ, Johnson BL, et al. Hypopigmentation in tinea versicolor. A histochemical and electron microscopic study. *Int J Dermatol* 1973; 12: 48-58.
- 3 Karaoui R, Bou-Resli M, Alzaid NS, et al. Tinea versicolor; ultrastructural studies on hypopigmented and hyperpigmented skin. *Dermatologica* 1981; 162: 69-73.
- 4 Borgers M, Cauwenbergh G, Van De M, et al. Pityriasis versicolor and *Pityrosporum ovale*: morphogenetic and ultrastructural considerations. *Int J Dermatol* 1987; 26: 586-589.
- 5 Allen HB, Charles CR, Johnson BL. Hyperpigmented tinea versicolor. *Arch Dermatol* 1976; 112: 1110-1112.
- 6 Breanthenach AS, Nazzaro-Porro M, Martin B. Ultrastructure of the skin in pityriasis versicolor. *Minerva Dermatol* 1973; 10: 457-469.
- 7 Galdari I, El Komy M. Tinea versicolor: histologic and ultrastructural investigation of pigmentary changes. *Int J Dermatol* 1992; 31: 253-256.
- 8 Dotz WI, Henrikson DM, Yu GSM, et al. Tinea versicolor: a light and electron microscopy study of hyperpigmented skin. *J Am Acad Dermatol* 1985; 12: 37-44.
- 9 Pathak MA, Fitzpatrick TB. Preventive treatment of sunburn, dermatoheliosis and skin cancer with sun-protective agents. In: Fitzpatrick TB, Eisen AZ, Wolff K, et al., eds. *Dermatology in General Medicine*, 4th edn. New York: McGraw-Hill, 1993: 1689-1717.
- 10 Rippon JW. *Medical Mycology: the Pathogenic Fungi and the Pathogenic Actinomycetes*. Philadelphia: WB Saunders, 1988: 154-159.
- 11 Borelli D, Jacobs PH, Nall I. Tinea versicolor: epidemiologic, clinical and therapeutic aspects. *J Am Acad Dermatol* 1991; 25: 300-305.
- 12 Faergemann J. Pityriasis versicolor (tinea versicolor). In: Demis DJ, ed. *Clinical Dermatology*, Vol. 3, Unite 17-2. Philadelphia: Harper & Row, 1989: 1-10.
- 13 Gueho E, Midgley G, Guillot J. The genus *Malassezia* with description of four new species. *Antonie van Leeuwenhoek J Microbiol Serol* 1996; 69: 337-355.

This document is a scanned copy of a printed document. No warranty is given about the accuracy of the copy. Users should refer to the original published version of the material.